

The Role of Magnetic Resonance Enterography (MRE) in Management of Crohn's Disease

Dr. Jaafar Tahir Hassan^{1*}, Dr. Naser Abdullah Mohammed², Dr. Heero Ismail Faraj³

1. M.B.Ch.B.; F.K.B.M.S (Internal Medicine), trainee at Gastroenterology department of Kurdistan Board; KCGH in Sulaimani city-Kurdistan region/Iraq

2. M.B.Ch.B.; F.I.B.M.S (Radiology), Assistant Professor at KCGH in Sulaimani city-Kurdistan region/Iraq

3. Gastroenterologist and Hepatologist at KCGH in Sulaimani city-Kurdistan region/Iraq

* Corresponding Author jaafarbarzanii@gmail.com

Original Article

Abstract

Background: The Crohn's disease is a chronic inflammatory bowel disease with increasing incidence in Iraq and Kurdistan region in last decade. The imaging modalities have great advantages in diagnosis and follow up of the disease.

Objective: To assess the epidemiology, clinical manifestations and treatment characteristics of patients with Crohn's disease and evaluating the role magnetic resonance enterography in management of Crohn's.

Patients and Method: This study was an observational cross sectional study implemented in Kurdistan center for Gastroenterology and Hepatology (KCGH) in Sulaimani city and Hawler Gastroenterology and hepatology Center (HGHC) Erbil city-Kurdistan region/Iraq during the period of eight months from 1st of January to 31st of August, 2022 convenient sample of fifty patients with Crohn's disease. The specialist responsible decided to do magnetic resonance enterography, depending on clinical status of the patients, laboratory results and lack of response to treatments.

Results: The final decision regarding Crohn's disease treatment was newly started (14%), or no change (26%) or change; biological (48%), surgery (8%), biological, surgery and percutaneous drainage (2%) and biological and surgery (2%). Common magnetic resonance enterography findings were small bowel thickening, wall enhancement, Comb sign and lymph node enlargement. There was a significant association between magnetic resonance enterography findings and treatment decision ($p=0.003$). Other factors related to treatment decision in CD are disease duration, Harvey-Bradshaw index of severity, fecal calprotectin test and C-reactive protein test.

Conclusions: The magnetic resonance enterography has a major role in evaluation of Crohn's disease management.

Keywords: Crohn's disease, magnetic resonance enterography, Treatment decision.

Received : March, 2023, **Published:** June, 2023

Citation: Hassan J.T, Mohammed N.A, Faraj H.I The Role of Magnetic Resonance Enterography (MRE) in Management of Crohn's Disease. JMSP 2023; 9(2): 122-42

1. INTRODUCTION

The Crohn's disease (CD) is a chronic inflammatory bowel disease causing transmural and segmental inflammation of the intestinal wall and might be accompanied by extra-luminal complications. The CD may affect any part of the digestive tract, but 70% of CD cases are reported in small intestine (1). The incidence of CD reached to about 20.2/100,000 in USA and about 12.7/100,000 in Europe, while it is 5/100,000 in Asia (2, 3). Generally, the incidence of CD is highly related to westernization of society lifestyles. The Crohn's disease incidence is increased in Iraq and specifically in Kurdistan region in last decade due to modernization of community and socioeconomic changes (4). Etiology of CD is multi-factorial involved the genetics and environmental effects. The common risk factors are genetic factors and others like smoking, low carbohydrate diet, non-steroidal anti-inflammatory drug and intestinal microbiome changes (5, 6). The pathogenesis of CD is mainly related to improper regulation of mucosal immune response in addition to environmental and genetic factors (7). The main clinical symptom of CD is watery diarrhea (8) and other symptoms which are varying in severity according to involvement site of gastrointestinal tract (9). The abdominal pain might precede the diagnosis of CD in years localizing in right lower abdomen and sometimes accompanied with bowel movement. The diarrhea is commonly watery and sometimes bloody. The weight loss is attributed anorexia, diarrhea and mal-absorption (8, 9). In general, about one-third of patients have other complications at time of CD diagnosis such as colitis, ileocolitis, ileitis, penetrated or strictured intestine (10). Extra-intestinal manifestations present in 21% of CD patients; commonly skin manifestations (like pyoderma gangrenosum), followed by; hepato-biliary, musculoskeletal, genitourinary, respiratory, ocular and cardiovascular manifestations (11).

Diagnosis of CD is not dependable on single standard test, but it relies on combined clinical, laboratory and cross sectional imaging in addition to endoscopy and histology evaluation (12-14). The ileocolonoscopy and biopsy are essential in establishing inflammatory bowel disease diagnosis with help of endoscopy in detecting lesions, stenosis and fistulae with perianal lesions (14, 15). The small bowel capsule endoscopy and cross sectional imaging must be implemented in patients with clinical suspicion of CD but with normal endoscopy (16). Additionally, new cases of CD required small bowel evaluation by ultrasound (US), magnetic

resonance enterography (MRE), and/or capsule endoscopy (17). The imaging, specifically the US and MRE, is nowadays essential in diagnosis and follow up of CD patients. For diagnosis, radiology imaging played a major role in assessment of CD disease extent and detection of complications (like fistula, abscesses and strictures) in addition to measure the disease activity. In follow-up, the imaging is helpful in disease activity assessment which is required for evaluation of treatment response and to diagnosing the complications (18, 19). Recently, the MRE is considered as the common accepted method in assessing small intestine among CD patients (20-22). Lack of ionizing radiation is the main advantage of MRE that facilitated its use in pregnancy, children and follow up of known cases of CD which all with other advantages put the MRE today as regarded as the gold standard method (23). Similar to diagnosis, there is no reference standard test used in treatment assessment of CD. The CD Activity Index (CAI) is not a reliable measure of underlying inflammation, while the mucosal healing is helpful in lowering relapse rates, hospitalization rates and need for surgery (24). Assessing transmural healing is important in evaluation of treatment response. For that, the imaging is useful for treatment assessment by evaluating transmural healing. Many authors reinforced the role of cross sectional imaging techniques in therapy monitoring in CD (25, 26). The MRE could detect the extent and activity of CD depending on wall thickness and intravenous contrast enhancement (27). The computed tomography enterography (CTE) has close accuracy of MRE in diagnosis and treatment assessment of CS, but the MRE is preferable due to its safety and usefulness in children and pregnancy (28, 29). In general, the MRE is highly preferred than different techniques in diagnosis and follow up of CD due to its lack of ionizing radiation, panoramic nature, accurate contrast resolution and multi-parametric nature of its inherent features (30). This study aimed to assess the epidemiology, clinical manifestations and treatment characteristics of patients with Crohn's disease and evaluating the role magnetic resonance enterography in management of Crohn's.

2. PATIENTS and METHODS

This study was an observational cross sectional study implemented in Kurdistan center for Gastroenterology and Hepatology (KCGH) in Sulaimani city and Hawler Gastroenterology and hepatology Center (HGHC) Erbil city-Kurdistan region/Iraq during the period of eight months from 1st of January to 31st of August, 2022. The studied population was all patients with Crohn's disease admitted to KCGH and HGHC during study period. Inclusion criteria were patients with any age and gender diagnosed with Crohn's disease and willingness to participate in the study. Exclusion criteria were patients with renal dysfunction, patients with hypersensitivity to contrast and Hyoscine, patients with cardiac pacemakers or any other metallic implants in their body and patients refused to participate in the study. The study ethics were implemented in regard to Helsinki Declaration by approval of Ethical Committee of Kurdistan Board, documented approval of health authorities and informed oral consent of selected patients. A convenient sample of fifty patients with Crohn's disease was enrolled in current study after eligibility to inclusion and exclusion criteria. Data of patients was collected directly from patients by researcher or from their saved records through a prepared questionnaire designed by the researcher according to previous literatures 17, 23, 27. The questionnaire included general characteristics of patients with Crohn's disease (age, gender, age at diagnosis, smoking status, previous surgery and disease duration), clinical features of patients with Crohn's disease , extra-intestinal manifestations of patients with Crohn's disease, severity index and investigations findings of patients with Crohn's disease (Harvey-Bradshaw Index, Hb level, WBC level, platelets level, albumin level, fecal calprotectin and C-reactive protein test), treatment and colonoscopy characteristics of patients with Crohn's disease, Magnetic Resonance Enterography findings of patients with Crohn's disease (MRE site of involvement and MRE findings) and decision on treatment (newly started, no change, or change; biological, surgery, biological, surgery and percutaneous drainage and biological and surgery). The specialist responsible decided to do MRE, depending on clinical status of the patients, laboratory results and lack of response to treatments. The MRE was done in KCGH/Sulaimani and Rizgary Hospital/Erbil with (MRI SIEMENS, 1.5 Tesla) equipment. Regarding the outcomes, the MRE had significant effect on making decision regarding management of Crohn's disease patients whether in the form of medical management including

optimization of medications and starting new drugs or surgical interventions and had also role in diagnosing Crohn's Disease. Also clinical status of the cases (HBI) and abnormal laboratory results had significant impact of decision on treatment of Crohn's Disease patients. The HBI was measured in regard to general wellbeing, abdominal pain, number of liquid stools per day, abdominal mass and complications. HBI less than 5 mean remission, HBI 5-7 mean mild disease, HBI 8-16 mean moderate disease and HBI more than 16 mean severe disease. The patients' information were entered and interpreted statistically by SPSS program-26. Suitable statistical tests (Chi square and Fishers exact tests) for data were implemented accordingly and p value of ≤ 0.05 was significant.

3. RESULTS

This study included fifty patients with Crohn's Disease (CD) presented with mean age of (31.1 years) and ranged between 10-70 years; 10% of them were at age of less than 20 years and 10% of them were at age of 40 years and more. The male gender of CD patients was more than females (74% vs. 26%). Age at diagnosis of CD was mainly in patients' age of 17-40 years. Smoking was positive in 26% of CD patients, while 30% of them had positive history of previous surgery (8 cases with history of appendectomy and 7 cases with history of perianal surgery). Mean CD disease duration was (2.8 years); 18% of CD patients had disease duration of less than one year and 54% of them had disease duration of more than two years as shown in (**Table 1**). The common clinical features of CD were abdominal pain (92%), diarrhea (60%), weight loss (30%), etc. (**Figure 1**). The extra-intestinal manifestations were present in 14% of CD patients; mainly oral, peripheral and sacroilitis, etc. (**Figure 2**). The HBI was classified into; remission (24%), mild (32%), moderate (42%) and severe (2%). The investigations of CD patients showed anemia (44%), high WBC (12%), high platelets (8%), low albumin level (34%), elevated fecal calprotectin (76%) and elevated CRP (54%) as shown in (**Table 2**). Ten percent of CD patients were not taking treatment, while common treatment of CD patients was Azathioprin (80%), corticosteroids (48%) and biological (36%). The colonoscopy showed that common site of CD was terminal ileum (40%), followed by; terminal ileum and ileocecal (32%), terminal ileum and colon (8%), terminal ileum, ileocecal and colon (8%) and colon (6%), etc. as shown in (**Table 3**). Final decision regarding CD treatment was newly started (14%), or no change (26%) or change; biological (48%), surgery (8%), biological, surgery and

percutaneous drainage (2%) and biological and surgery (2%). The MRE of CD patients showed that main site of involvement were terminal ileum (30%), ileum and terminal ileum (24%), jejunum, ileum and terminal ileum (16%), terminal ileum and colon (10%) and ileum, terminal ileum and colon (8%), etc. Common MRE findings were Small bowel thickening (SBT), wall enhancement (WE), Comb sign (CS) and LN enlargement (28%), SBT, WE, CS, stricture and LN enlargement (16%), BT, WE, CS and LN enlargement (10%), SBT and WE (10%), etc. as shown in (**Table 4**). No significant differences were observed according to decision of treatment regarding age ($p=0.14$), gender ($p=0.62$), age at diagnosis ($p=0.13$), smoking ($p=0.4$), previous surgery ($p=0.7$) and extra-intestinal manifestations ($p=0.22$). There was a highly significant association between longer disease duration and treatment change ($p<0.001$) as shown in (**Table 5**). A significant association was observed between CD patients with remission phase and no change decision regarding treatment, while moderate and severe CD was associated with change decision ($p=0.004$). No significant differences were observed according to decision of treatment regarding Hb level ($p=0.67$), WBC level ($p=0.13$), platelets level ($p=0.18$), albumin level ($p=0.13$) and colonoscopy site of involvement ($p=0.18$). There was a significant association between elevated fecal calprotectin and change decision ($p=0.005$). A significant association was observed between elevated CRP test and change decision ($p=0.007$) as shown in (**Table 6**). No significant differences were observed regarding decision of treatment according MRE site of involvement ($p=0.34$). There was a significant association between MRE findings and treatment decision ($p=0.003$), 35.7% of patients with change decision were significantly had small bowel thickening, wall enhancement, Comb sign and LN enlargement as shown in (**Table 7**).

Table 1. General characteristics of CD patients.

Variable	No.	%	
Age*	<20 years	5	10.0
	20-29 years	15	30.0
	30-39 years	25	50.0
	≥40 years	5	10.0
Gender	Male	37	74.0
	Female	13	26.0
Age at diagnosis	<17 years	4	8.0
	17-40 years	42	84.0
	>40 years	4	8.0
Smoking status	Yes	13	26.0
	No	37	74.0
Previous surgery	Yes	15	30.0
	No	35	70.0
Disease duration**	<1 years	9	18.0
	1-2 years	14	28.0
	>2 years	27	54.0
	Total	50	100.0

* Mean age ± SD is (31.1±10.6 years). ** mean disease duration ± SD (2.8±1.7 years).

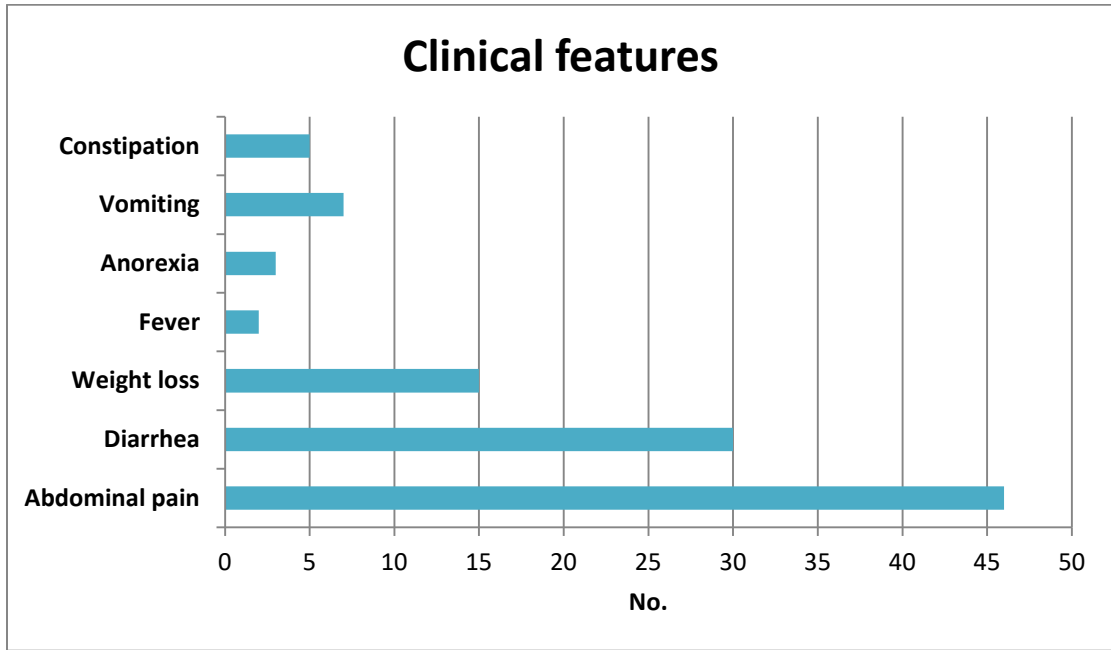


Figure 1: Clinical features of CD patients.

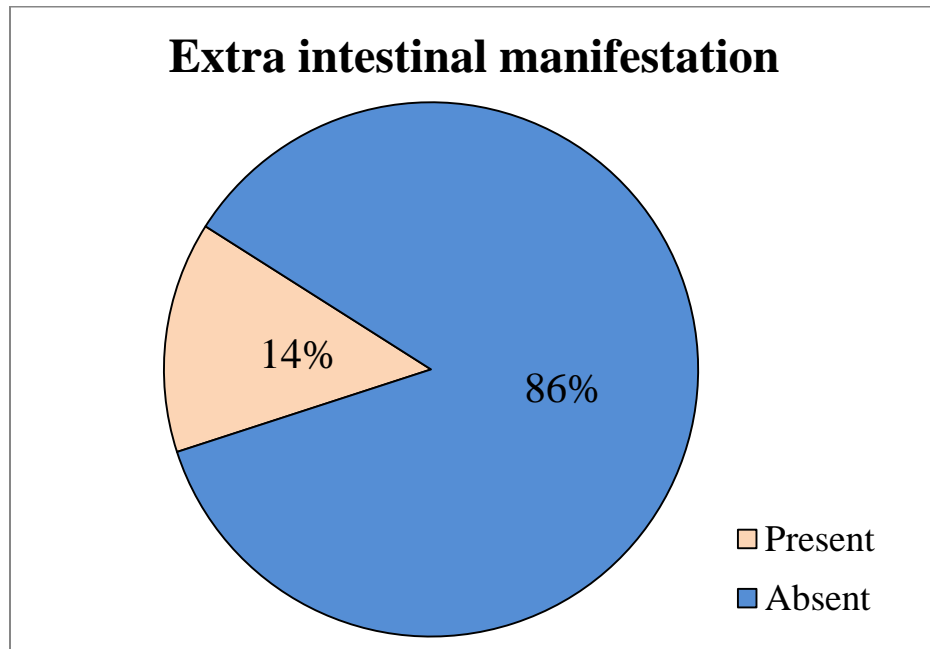


Figure 2: Extra-intestinal manifestation of CD patients.

Table 2. Severity index and investigations findings of CD patients

Variable		No.	%
Harvey-Bradshaw Index (HBI)	Remission	12	24.0
	Mild	16	32.0
	Moderate	21	42.0
	Severe	1	2.0
Hb level	Normal	22	44.0
	Anemic	28	56.0
WBC level	Normal	44	88.0
	High	6	12.0
Platelets level	Low	1	2.0
	Normal	45	90.0
	High	4	8.0
Albumin level	Normal	33	66.0
	Low	17	34.0
Fecal calprotectin	Elevated	38	76.0
	Normal	12	24.0
CRP	Elevated	27	54.0
	Normal	23	46.0
	Total	50	100.0

Table 3. Treatment and colonoscopy characteristics of CD patients.

Variable		No.	%
Treatment	Positive	45	90.0
	Negative	5	10.0
Colonoscopy site of involvement	Terminal ileum	20	40.0
	Ileocecal	2	4.0
	Colon	3	6.0
	Terminal ileum and ileocecal	16	32.0
	Terminal ileum and colon	4	8.0
	Ileocecal and colon	1	2.0
	Terminal ileum, ileocecal and colon	4	8.0
	Total	50	100.0
Azathioprin		40	80.0
Corticosteroids		24	48.0
Biological (Infliximab & Adalimumab)		18	36.0

Table 4. Magnetic Resonance Enterography (MRE) findings of CD patients and decision on treatment.

Variable	No.	%
Decision on treatment		
Newly started	7	14
No change	13	26
Biological	24	48
Surgery	4	8
Biological, surgery and percutaneous drainage	1	2
Biological and surgery	1	2
MRE site of involvement		
Jejunum	1	2
ileum	1	2
Terminal ileum	15	30
Colon	2	4
Jejunum and terminal ileum	1	2
Ilium and terminal ileum	12	24
Terminal ileum and colon	5	10
Ilium, terminal ileum and colon	4	8
Jejunum, ileum and terminal ileum	8	16
Jejunum and colon	1	2
MRE findings		
SBT	2	4
WE	3	6
SBT, WE, stricture and LN enlargement	3	6
SBT, wall enhancement and LN enlargement	5	10
Small bowel thickening, WE, CS and LN enlargement	14	28
SBT, WE and CS	1	2
SBT, WE, fistula, abscess and LN enlargement	1	2
SBT, WE and fistula	1	2
SBT and WE	5	10
SBT, WE, CS, stricture and LN enlargement	8	16
SBT and fistula	1	2
SBT, WE, stricture, fistula and LN enlargement	2	4
SBT, WE, CS, fistula and LN enlargement	1	2
Stricture, fistula and LN enlargement	1	2
WE and stricture	1	2
WE and LN enlargement	1	2

Table 5. Distribution of patients' general characteristics according to final decision.

Variable		Decision						P.value
		Newly started		No change		Change		
		No.	%	No.	%	No.	%	
Age	<20 years	2	28.6	0	-	3	10.7	0.14 ^{NS}
	20-29 years	2	28.6	6	40.0	7	25.0	
	30-39 years	1	14.3	8	53.3	16	57.1	
	≥40 years	2	28.6	1	6.7	2	7.1	
Gender	Male	6	85.7	10	66.7	21	75.0	0.62 ^{NS}
	Female	1	14.3	5	33.3	7	25.0	
Age at diagnosis	<17 years	1	14.3	0	-	3	10.7	0.13 ^{NS}
	17-40 years	4	57.1	14	93.3	24	85.7	
	>40 years	2	28.6	1	6.7	1	3.6	
Smoking status	Yes	2	28.6	2	13.3	9	32.1	0.4 ^{NS}
	No	5	71.4	13	86.7	19	67.9	
Previous surgery	No	4	57.1	11	73.3	20	71.4	0.7 ^{NS}
	Yes	3	42.9	4	26.7	8	28.6	
Disease duration	<1 years	7	100.0	1	6.7	1	3.6	<0.001 ^S
	1-2 years	0	-	5	33.3	9	32.1	
	>2 years	0	-	9	60.0	18	64.3	
Extra-intestinal manifestation	Yes	1	14.3	2	13.3	4	14.3	0.9 ^{NS}
	No	6	85.7	13	86.7	24	85.7	

S=Significant, NS=Not significant.

Table 6. Distribution of severity index, investigations and colonoscopy site findings according to final decision.

Variable		Decision						P-Value
		Newly started		No change		Change		
		No.	%	No.	%	No.	%	
HBI	Remission	0	-	9	60.0	3	10.7	0.004 ^S
	Mild	3	42.9	5	33.3	8	28.6	
	Moderate	4	57.1	1	6.7	16	57.1	
	Severe	0	-	0	-	1	3.6	
Hb level	Normal	3	42.9	8	53.3	11	39.3	0.67 ^{NS}
	Anemic	4	57.1	7	46.7	17	60.7	
WBC level	Normal	5	71.4	15	100.0	24	85.7	0.13 ^{NS}
	High	2	28.6	0	-	4	14.3	
Platelets level	Low	0	-	0	-	1	3.6	0.18 ^{NS}
	Normal	5	71.4	15	100.0	25	89.3	
	High	2	28.6	0	-	2	7.1	
Albumin level	Normal	4	57.1	13	86.7	16	57.1	0.13 ^{NS}
	Low	3	42.9	2	13.3	12	42.9	
Fecal	Elevated	7	100.0	7	46.7	24	85.7	0.005 ^S
	Normal	0	-	8	53.3	4	14.3	
CRP	Elevated	5	71.4	3	20.0	19	67.9	0.007 ^S
	Normal	2	28.6	12	80.0	9	32.1	
Colonoscopy site of involvement	Terminal ileum	5	71.4	9	60.0	6	21.4	0.18 ^{NS}
	Ileocecal	1	14.3	1	6.7	0	.0	
	Colon	0	-	0	-	3	10.7	
	Terminal ileum and ileocecal	1	14.3	3	20.0	12	42.9	
	Terminal ileum and colon	0	-	1	6.7	3	10.7	
	Ileocecal and colon	0	-	0	.0	1	3.6	
	Terminal ileum, ileocecal and colon	0	-	1	6.7	3	10.7	

S=Significant, NS=Not significant.

Table 7: Distribution of MRE findings according to final decision.

Variable		Decision						P-Value
		Newly started		No change		Change		
		No.	%	No.	%	No.	%	
MRE site of involvement	Jejunum	0	-	1	6.7	0	-	0.34 ^{NS}
	Ileum	0	-	1	6.7	0	-	
	Terminal ileum	1	14.3	7	46.7	7	25.0	
	Colon	0	-	0	.0	2	7.1	
	Jejunum and	0	-	1	6.7	0	-	
	Ilium and	2	28.6	1	6.7	9	32.1	
	Terminal ileum	0	.0	1	6.7	4	14.3	
	Ilium, terminal	1	14.3	1	6.7	2	7.1	
	Jejunum, ileum	3	42.9	2	13.3	3	10.7	
	Jejunum and	0	-	0	-	1	3.6	
MRE findings	SBT	0	-	2	13.3	0	-	0.003 ^S
	WE	0	-	3	20.0	0	.0	
	SBT, WE,	0	-	0	-	3	10.7	
	SBT, WE and	3	42.9	2	13.3	0	-	
	SBT, WE, CS	2	28.6	2	13.3	10	35.7	
	SBT, WE and	1	14.3	0	-	0	-	
	SBT, WE,	0	-	0	-	1	3.6	
	SBT, WE and	0	-	0	-	1	3.6	
	SBT and WE	0	-	4	26.7	1	3.6	
	SBT, WE, CS,	0	-	1	6.7	7	25.0	
	Small bowel	0	-	0	-	1	3.6	
	SBT, WE,	0	-	0	-	2	7.1	
	stricture, fistula	0	-	0	-	1	3.6	
	SBT, WE, CS,	1	14.3	0	-	0	-	
	Stricture, fistula	0	-	0	-	1	3.6	
	WE and stricture	0	-	0	-	1	3.6	
	WE and LN	0	-	1	6.7	0	-	

S=Significant, NS=Not significant.

4. DISCUSSION

The Crohn's disease is a heterogeneous disorder characterized by multi-factorial pathogenesis. Technology advancement in imaging techniques for diagnosis and follow up of CD is aiming in reducing the invasiveness and fastening the treatment decisions as well as assessing treatment response (31). The current study showed that final decision regarding CD treatment was newly started (14%), or no change (26%) or change to; biological (48%), surgery (8%), biological, surgery and percutaneous drainage (2%) and biological and surgery (2%). These findings are similar to reports of many literatures such as Kumar et al. (32) study in United Kingdom and Im et al. (33) study in South Korea which all stated that changing treatments paradigms is essential in CD management and it is dependable on patientsv characteristics, preferences and the disease activity. It was shown that CD management in general relies on its severity, risk stratification of patients, their preferences and other clinical factors such as age of onset (34). In our study, the MRE of CD patients showed that main site of involvement were terminal ileum (30%), ileum and terminal ileum (24%), jejunum, ileum and terminal ileum (16%), terminal ileum and colon (10%) and ileum, terminal ileum and colon (8%), etc. These finding are in agreement with results of Tsai et al. (35) retrospective study in United States which reported high involvement of ileum detected by MRE in patients with CD. Caprilli study (36) in Italy documented that some genetic and environmental factors play role in higher incidence of CD in terminal ileum. Our study found that common MRE findings in CD patients were Small bowel thickening (SBT), wall enhancement (WE), Comb sign (CS) and LN enlargement (28%), SBT, WE, CS, stricture and LN enlargement (16%), BT, WE, CS and LN enlargement (10%), SBT and WE (10%). These findings are in agreement with results of Biernacka et al. (37) study in Poland which reported that thickening, strictures and lymph nodes involvement detected by MRE are independent predictive factors in CD diagnosis and assessment. Mantarro et al. (38) study in Italy stated that magnetic resonance enterography is essential in determination of CD extension, disease activity and identification of complications without risk of ionizing radiation that made it very suitable for younger age population and pregnancy. The present study showed a highly significant association between longer disease duration and treatment change ($p < 0.001$). This finding is consistent with results of Cosnes et al. (39) follow up study in France which reported that longer duration of CD is accompanied with

treatment regimen changes. Our study found a significant association between CD patients with remission phase and no change decision regarding treatment, while moderate and severe CD was associated with change decision ($p=0.004$). This finding coincides with reports of Sulza et al. (40) study in Switzerland which stated that changes in CD treatment is dependable mainly on current disease activity of CD. In our study, there was a significant association between elevated fecal calprotectin and change decision ($p=0.005$). Similarly, Bourgonje et al. (41) study in Netherlands found that fecal calprotectin is positively correlated serum Th1- and Th17-associated cytokines and the fecal calprotectin is useful in treatment response assessment. Another retrospective study conducted in United Kingdom by Kennedy et al. (42) that measurement of fecal calprotectin is helpful in assessing CD progression. Our study showed also a significant association between elevated CRP test and change decision ($p=0.007$). This finding is parallel to results of many literatures such as Lin et al (43) study in China and Magro et al. (44) study in Portugal which all documented the significance of C-reactive protein test in predicting treatment response in Crohn's disease. In present study, there was a significant association between MRE findings and treatment decision ($p=0.003$), 35.7% of patients with change decision were significantly had small bowel thickening, wall enhancement, Comb sign and LN enlargement. This finding is similar to results of Messaris et al. (45) study in United States which found that MRE is helpful in treatment decision of CD in addition to its ability in disease severity characterization and monitoring of disease activity. Ahmad et al. (46) study in Saudi Arabia revealed that MRE is an accurate imaging technique for detection of small bowel activity in CD and in assessment of treatment response. This study concluded that magnetic resonance enterography has a major role in evaluation of Crohn's disease management. The magnetic resonance enterography is useful in assessment of treatment response and decisions regarding changes in treatment regimens. Other factors related to treatment decision in CD are disease duration, Harvey-Bradshaw index of severity, fecal calprotectin test and C-reactive protein test. This study recommended the use of magnetic resonance enterography in diagnosis and treatment response evaluation of patients with Crohn's disease.

5. CONCLUSIONS

This study concluded that magnetic resonance enterography has a major role in evaluation of Crohn's disease management. The magnetic resonance enterography is useful in assessment of treatment response and decisions regarding changes in treatment regimens. Other factors related to treatment decision in CD are disease duration, Harvey-Bradshaw index of severity, fecal calprotectin test and C-reactive protein test. This study recommended the use of magnetic resonance enterography in diagnosis and treatment response evaluation of patients with Crohn's disease.

Ethical Clearance:

Ethical issues were taken from the research ethics committee. Informed consent was obtained from each participant. Data collection was in accordance with the World Medical Association (WMA) declaration of Helsinki for the Ethical Principles for Medical Research Involving Human Subjects, 2013 and all information and privacy of participants were kept confidentially.

Conflict of interest: Authors declared none

Funding: None, self-funded by the authors

Acknowledgement

Gratitude and thanks for the staff of KCGH and HGHC in Kurdistan region.

6. REFERENCES

1. Gajendran M, Loganathan P, Catinella AP, Hashash JG. A comprehensive review and update on Crohn's disease. *Dis-A-Mon* 2018; 64: 20–57.
2. Mkombe AE. Inflammatory bowel disease: an expanding global health problem. *Clin Med Insights Gastroenterol* 2013; 6:12731. Available from: <https://doi.org/10.4137/CGast.S12731>
3. Ye Y, Pang Z, Chen W, Ju S, Zhou C. The epidemiology and risk factors of inflammatory bowel disease. *Int J Clin Exp Med* 2015; 12:22529.
4. Alshekhani MAM, Salim BF, Mohialdeen ZN, Amin BJH. Clinical Characteristic of Inflammatory Bowel Disease Diagnosed in Kurdistan Center for Gastroenterology and Hepatology (Kcgh) – Asulaimaiyah-Iraqi Kurdistan-Iraq. *Gastroint Hepatol Dig Dis* 2020; 3(2): 1-7.

5. Gevers D, Kugathasan S, Denson LA, Vázquez-Baeza Y, Van Treuren W, Ren B, et al. *The Treatment-Naive Microbiome in New-Onset Crohn's Disease*. *Cell Host Microbe* 2014; 15: 382–392.
6. Kostic AD, Xavier RJ, Gevers D. *The Microbiome in Inflammatory Bowel Disease: Current Status and the Future Ahead*. *Gastroenterology* 2014; 146: 1489–1499.
7. Xu XR, Liu CQ, Feng BS, Liu ZJ. *Dysregulation of mucosal immune response in pathogenesis of inflammatory bowel disease*. *World J Gastroenterol* 2014; 220:3255–3264. Available from: <https://doi.org/10.3748/wjg.v20.i12.3255>
8. Flynn S, Eisenstein S. *Inflammatory Bowel Disease Presentation and Diagnosis*. *Surg Clin N Am* 2019; 99: 1051–1062.
9. Sawczenk A, Sandhu BK. *Presenting features of inflammatory bowel disease in Great Britain and Ireland*. *Arch Dis Child* 2003; 88: 995–1000.
10. Thia KT, Sandborn WJ, Harmsen WS, Zinsmeister AR, Loftus EV Jr. *Risk factors associated with progression to intestinal complications of Crohn's disease in a population-based cohort*. *Gastroenterology* 2010; 139:1147–1155. Available from: <https://doi.org/10.1053/j.gastro.2010.06.070>
11. Papanikolaou I, Kagouridis K, A Papiris S. *Patterns of airway involvement in inflammatory bowel diseases*. *World J Gastrointest Pathophysiol* 2014; 5: 560–569.
12. Maaser C, Sturm A, Vavricka SR, Kucharzik T, Fiorino G, Annese V, et al. *ECCO-ESGAR Guideline for Diagnostic Assessment in IBD Part 1: Initial diagnosis, monitoring of known IBD, detection of complications*. *J Crohn's Colitis* 2018; 13: 144–164K.
13. Gomollón F, Dignass A, Annese V. *ECCO. Third European evidence-based consensus on the diagnosis and management of Crohn's disease 2016. Part 1: Diagnosis and medical management*. *J. Crohn's Colitis* 2017; 11: 3–25.
14. Benedetti G, Mori M, Panzeri MM, Barbera M, Palumbo D, Sini C, et al. *CT-derived radiomic features to discriminate histologic characteristics of pancreatic neuroendocrine tumors*. *La Radiol Med* 2021; 126: 745–760.
15. Danti G, Flammia F, Matteuzzi B, Cozzi D, Berti V, Grazzini G, et al. *Gastrointestinal neuroendocrine neoplasms (GI-NENs): Hot topics in morphological, functional, and prognostic imaging*. *La Radiol Med* 2021; 126: 1497–1507.
16. Kopylov U. *Diagnostic yield of capsule endoscopy versus magnetic resonance enterography and small bowel contrast ultrasound in the evaluation of small bowel Crohn's disease: Systematic*

- review and meta-analysis. *Dig Liver Dis* 2017; 49: 854–863.
17. Qiu Y, Mao R, Chen BL, Li XH, He Y, Zeng ZR. Systematic review with meta-analysis: Magnetic resonance enterography vs. computed tomography enterography for evaluating disease activity in small bowel Crohn's disease. *Aliment Pharmacol Ther* 2014; 40: 134–146.
 18. Trimboli P, Castellana M, Virili C, Havre RF, Bini F, Marinozzi F, et al. Performance of contrast-enhanced ultrasound (CEUS) in assessing thyroid nodules: A systematic review and meta-analysis using histological standard of reference. *La Radiol Med* 2020; 125: 406–415.
 19. Di Serafino M, Vallone G. The role of point of care ultrasound in radiology department: Update and prospective. A statement of Italian college ultrasound. *La Radiol Med* 2020; 126: 636–641.
 20. Bertocchi E, Barugola G, Nicosia L, Mazzola R, Ricchetti F, Dell'Abate P, et al. A comparative analysis between radiation dose intensification and conventional fractionation in neoadjuvant locally advanced rectal cancer: A monocentric prospective observational study. *La Radiol Med* 2020; 125: 990–998.
 21. Wnorowski AM, Guglielmo FF, Mitchell DG. How to perform and interpret cine MR enterography. *J Magn Reson Imaging* 2015; 42: 1180–1189.
 22. Jesuratnam-Nielsen K, Løgager VB, Rezanavaz-Gheshlagh B, Munkholm P, Thomsen HS. Plain magnetic resonance imaging as an alternative in evaluating inflammation and bowel damage in inflammatory bowel disease—a prospective comparison with conventional magnetic resonance follow-through. *Scand J Gastroenterol* 2015; 50: 519–527.
 23. Biondi M, Bicci E, Danti G, Flammia F, Chiti G, Palumbo P, et al. The Role of Magnetic Resonance Enterography in Crohn's Disease: A Review of Recent Literature. *Diagnostics* 2022; 12: 1236. Available from: <https://doi.org/10.3390/diagnostics12051236>
 24. Colombel J, Rutgeerts PJ, Sandborn WJ, Yang M, Camez A, Pollack PF, et al. Adalimumab Induces Deep Remission in Patients With Crohn's Disease. *Clin Gastroenterol Hepatol* 2013; 12: 414–422.e5.
 25. Kucharzik T, Wittig BM, Helwig U, Börner N, Rössler A, Rath S, et al. Use of Intestinal Ultrasound to Monitor Crohn's Disease Activity. *Clin Gastroenterol Hepatol* 2016; 15: 535–542.e2
 26. Stoppino LP, Della Valle N, Rizzi S, Cleopazzo E, Centola A, Iamele D, et al. Magnetic resonance enterography changes after antibody to tumor necrosis factor (anti-TNF) alpha therapy in Crohn's disease: Correlation with SES-CD and clinical-biological markers. *BMC Med Imaging* 2016; 16: 1–9.
 27. Qiu Y, Mao R, Chen BL, Li XH, He Y, Zeng ZR. Systematic review with meta-analysis: Magnetic

- resonance enterography vs. computed tomography enterography for evaluating disease activity in small bowel Crohn's disease. *Aliment Pharmacol Ther* 2014; 40: 134–146.
28. Sun J, Yang L, Zhou Z, Zhang D, Han W, Zhang Q, et al. Performance evaluation of two iterative reconstruction algorithms, MBIR and ASIR, in low radiation dose and low contrast dose abdominal CT in children. *La Radiol Med* 2020; 125: 918–925.
29. Masjedi H, Zare MH, Siahpoush NK, Razavi-Ratki SK, Alavi F, Shabani M. European trends in radiology: Investigating factors affecting the number of examinations and the effective dose. *La Radiol Med* 2019; 125: 296–305.
30. Panés J, Bouzas R, Chaparro M. Systematic review: The use of ultra-sonography, computed tomography and magnetic resonance imaging for the diagnosis, assessment of activity and abdominal complications of Crohn's disease. *Aliment Pharmacol Ther* 2011; 34: 125–145.
31. Peñate Medina T, Kolb JP, Hüttmann G, Huber R, Peñate Medina O, Ha L, et al. Imaging Inflammation - From Whole Body Imaging to Cellular Resolution. *Front Immunol* 2021; 12:692222.
32. Kumar A, Cole A, Segal J, Smith P, Limdi JK. A review of the therapeutic management of Crohn's disease. *Therap Adv Gastroenterol* 2022; 15:17562848221078456.
33. Im JP, Ye BD, Kim YS, Kim JS. Changing treatment paradigms for the management of inflammatory bowel disease. *Korean J Intern Med* 2018; 33(1):28-35.
34. Cushing K, Higgins PDR. Management of Crohn Disease: A Review. *JAMA* 2021; 325(1):69-80.
35. Tsai R, Mintz A, Lin M, Mhlanga J, Chiplunker A, Salter A, et al. Magnetic resonance enterography features of small bowel Crohn's disease activity: an inter-rater reliability study of small bowel active inflammation in clinical practice setting. *Br J Radiol* 2019; 92(1099):20180930.
36. Caprilli R. Why does Crohn's disease usually occur in terminal ileum? *Journal of Crohn's and Colitis* 2008; 2 (4): 352–356. Available from: <https://doi.org/10.1016/j.crohns.2008.06.001>
37. Biernacka KB, Barańska D, Matera K, Podgórski M, Czkwianianc E, Szabelska-Zakrzewska K, et al. The value of magnetic resonance enterography in diagnostic difficulties associated with Crohn's disease. *Pol J Radiol* 2021; 86:e143-e150.
38. Mantarro A, Scalise P, Guidi E, Neri E. Magnetic resonance enterography in Crohn's disease: How we do it and common imaging findings. *World J Radiol* 2017; 9(2): 46-54.
39. Cosnes J, Bourrier A, Nion-Larmurier I. Factors affecting outcomes in Crohn's disease over 15 years. *Gut* 2012; 61:1140-1145.
40. Sulza MC, Burrib E, Michettic P, Roglerd G, Peyrin-Biroulete L, Seiboldf F; on behalf of the Swiss

- IBDnet, an official working group of the Swiss Society of Gastroenterology. Treatment Algorithms for Crohn's Disease. Digestion 2020; 101 (Suppl 1):43-57.*
41. Bourgonje AR, von Martels JZH, de Vos P, Faber KN, Dijkstra G. Increased fecal calprotectin levels in Crohn's disease correlate with elevated serum Th1- and Th17-associated cytokines. *PLoS One* 2018; 13(2):e0193202.
 42. Kennedy NA, Jones GR, Plevris N, Patenden R, Arnott ID, Lees CW. Association Between Level of Fecal Calprotectin and Progression of Crohn's Disease. *Clin Gastroenterol Hepatol* 2019; 17(11):2269-2276.e4.
 43. Lin X, Qiu Y, Feng R, Chen B, He Y, Zeng Z, et al. Normalization of C-Reactive Protein Predicts Better Outcome in Patients With Crohn's Disease With Mucosal Healing and Deep Remission. *Clin Transl Gastroenterol* 2020; 11(2):e00135.
 44. Magro F, Rodrigues-Pinto E, Santos-Antunes J, Vilas-Boas F, Lopes S, Nunes A, et al. High C-reactive protein in Crohn's disease patients predicts nonresponse to infliximab treatment. *Journal of Crohn's and Colitis* 2014; 8 (2): 129–136. Available from: <https://doi.org/10.1016/j.crohns.2013.07.005>
 45. Messaris E, Chandolias N, Grand D, Pricolo V. Role of magnetic resonance enterography in the management of Crohn disease. *Arch Surg* 2010; 145(5):471-475.
 46. Ahmad R, Ajlan AM, Eskander AA, Alhazmi TA, Khashoggi K, Wazzan MA, et al. Magnetic resonance imaging in the management of Crohn's disease: a systematic review and meta-analysis. *Insights Imaging* 2021; 12(1):118.