



Fifteen- year Experience with Testicular Tumors at a Private Lab in Al-Najaf City, Iraq

Kaswer Musa Jaffar Al Toriahi¹, Muntadher Abdulla M.Jawad Zmezim^{2*}

1. MBChB, FICMS, Kufa Medical College, Department of Pathology, contact email: Qaswar.alturaihi@uokufa.edu.iq
2. MBChB., Candidate of the Arab Board for Health Specialization

*Corresponding Author , contact email : montadhardr6@gmail.com

Original Article

Summary

Testicular cancers are relatively rare cancers of young patients worldwide but the incidence rate is increasing specially in western society. However, There is a paucity of published studies regarding testicular tumors in Iraq, and Alnajaf city in particular. In this study we conduct a statistical histopathological analysis for the epidemiological and morphological characteristics of testicular cancers in a single private lab at Alnajaf city, Iraq between February 2005 and December 2020. All pathology reports were retrieved from a computerized database. During the period of study, 80 cases were diagnosed with testicular tumors representing (2.33%) of all male malignancies. The Histological typing of testicular tumors revealed that 75/80 cases had Germ cell tumors, contributed for (93.75%). Among them, Seminomas were the more frequent reported , (42.50%) , followed by MGCT (38.75%) , other subtypes were less frequent, and the least frequent subtypes were TSTM, Spermatocytic seminoma, and Leydig cell tumor in a rate of 1.25% for each. The mean ages of patients diagnosed with testicular malignancies in general and those with germ cell tumors were 33 years. Seminoma had a mean age of 40 years while those diagnosed with non-seminomas had a mean age of 26 years. Right sided testicular malignancies were significantly the more frequent , 47/80 (58.75%). Germ cell neoplasia in situ (GCNIS) was seen in 5 out of 75 cases with germ cell tumors (6.6%). In conclusion, testicular tumors are relatively uncommon and more likely to be a disease of young patient. Germ cell tumors were the most frequent, seminoma predominates over non- seminomatous germ cell tumors.

Keywords: Testicular Tumors, Epidemiology, types, pathogenesis, diagnosis

Article information: Received: February, 2022, Accepted and Published online March, 2022

How to cite this article: Al Toriahi K. M. Fifteen- year Experience with Testicular Tumors at a Private Lab in Al-Najaf City, Iraq. JMSP 2022; 8(1): 65- 78

1. INTRODUCTION

Testicular cancers relatively represent a small percentage of all malignancies in males globally. During 2020, 74458 cases has been reported worldwide with an age-standardized incidence rate of 1.8/100,000 ranging from 9.3/100,000 in Western Europe to 0.36/100,000 in Micronesia (1). The incidence is increasing in many countries especially the developed ones(2); however, mortality rates remain low(3). In Iraq, 219 new cases have been reported during 2020 representing 0.65% of all cancer sites (4).The adolescent & young adult men are most commonly affected , although, recently the presenting age is rising for affected patients , especially in seminoma(5). The 2016 WHO Classification of tumors of the testis and paratesticular tissue includes the following general categories : germ cell tumors derived from germ cell neoplasia in situ, germ cell tumors unrelated to germ cell neoplasia in situ, sex cord stromal tumors, tumor containing both germ cell and sex cord stromal elements, miscellaneous tumors of the testis, hematolymphoid tumors, tumors of collecting duct and rete testis, tumors of paratesticular structures, mesenchymal tumors of the spermatic cord and testicular adnexa and metastatic tumors(6). Germ cell tumor is the most common type making about 95 % of all testicular cancers (7). The main predisposing factors include : undescended testicle, abnormal sexual development, family history, testicular microliths in subfertility , previous history of germ cell tumors and genetic factors(8). Intratubular germ cell neoplasia is identified as the premalignant lesion with similar risk factors(9). In this study we conduct a statistical histopathological analysis for the epidemiological and morphological characteristics of testicular cancers in a single private lab at Alnajaf city as There is a paucity of published studies regarding testicular tumors in Iraq, and Alnajaf city in particular.

2. PATIENTS and METHODS

This is a cross-sectional study. The study population included all cases obtained in a single private lab at Al-najaf city, Iraq between February 2005 and December 2020. All pathology reports were retrieved from a computerized database. The diagnoses were most often made by two board certified pathologists. Total numbers of cases of testicular tumor were 80 analysed for: the histological subtype, the age of the patient, the side of tumor (left, right or bilateral), the history of undescended testis & presence of germ cell neoplasia in situ (GCNIS) . 3 cases of extratesticular germ cell tumors including a case with retroperitoneal

seminoma and 2 cases with mixed germ cell tumors , first, in a para-aortic lymph node & second, in two neck & mediastinal masses have been excluded because they were not associated with testicular biopsies. For descriptive purposes, the histological subtypes are divided into germ cell and non-germ cell tumors. The former is divided into : seminomas, non-seminomas & spermatocytic seminomas. The latter includes all testicular tumors other than germ cell tumors. 2016 WHO classification of tumors of the testis and paratesticular tissue is not followed as most cases had been diagnosed according to the previous versions of WHO classification.

Statistical analysis

Data were entered managed and analyzed using the statistical package for social sciences (SPSS) version 26 . Descriptive statistics expressed as frequencies, percentage , mean and standard deviation according to the variable types. Chi-square test was used to compare frequencies & Z-test was used to compare proportions . Bivariate correlation analysis (Spearman's test) was used to assess the inter-correlation between variables. Analysis of variances (ANOVA) test was used to compare mean age across the histological subtypes while student's t test was used to compare mean age across the main two types of tumor ; germ cell and non-germ cell tumors types . All statistical tests were applied under the assumption of two-tailed level of significance of 0.05.

3. RESULTS

The total number of cases received during fifteen years period (February 2005 to December 2020) was 40799, in males, a total of 3432 malignancies were reported, represented (8.41%) of all tumors received in the lab. Of them 80 cases were diagnosed with testicular tumors , represented (2.33%) of all male malignancies, (Figure 1) . The annual distribution of the 80 cases for the period 2005-2020, revealed variant rates in registered testicular tumors across the 15 years. The rates of registered testicular tumors ranged between 0.99% in the year 2017 to 6.06% in the year 2006 , with an average annual rate of 2.92% for the whole period, however, the difference among the annual rates was statistically insignificant, (P. value = 0.112), (Table 1 and Figures 2). The Histological typing of testicular tumors revealed that vast majority, 75/80 cases had Germ cell tumors, contributed for (93.75%), (P. value < 0.001, highly significant), (Figure 3). Furthermore, histopathological subtyping of the 80 testicular tumors, is summarized in (Table 2), where Seminomas were the more frequent reported ,

(42.50%) , followed by MGCT (38.75%) , other subtypes were less frequent, and the least frequent subtypes were TSTM, Spermatoctytic seminoma, and Leydig cell tumor in a rate of 1.25% for each. During the analysis of Patients' ages, the ages of two patients one with seminoma & the other with yolk sac tumor were unknown. The mean age of the remaining 78 patients was 33 years. The germ cell tumors had a mean age 33 years. (standard deviation of 14.5 years). Patients diagnosed with seminoma had a mean age of 40 years (standard deviation of 11 years) while those diagnosed with non-seminomas had a mean age of 26 years (standard deviation of 13 years). Regarding the side of tumors, right sided testicular malignancies were significantly the more frequent , 47/80 (58.75%), left sided ones represented (35%) and only one case with bilateral, however, in 4 cases (5%) the side of tumor was unreported (missed data), nonetheless, right sided tumors were the significantly more frequent (P. value = 0.001), (Table 3). Further analysis, using bivariate analysis, was performed to assess the possible inter-correlation between the patient's age , the annual rate, histological type and laterality of testicular tumors , result of these analyses are demonstrated in (Table 4), where the only significant correlation was found between age of patients and histological subtypes (R = 0.435, P < 0.01), therefore, analysis of variances (ANOVA) performed to compare mean age of patients with different histological subtype. This comparison revealed that patient with Spermatoctytic seminoma was the oldest one (75 years) , followed by patient with Leydig cell tumor (50 years), NHL (41 ± 5.7) years while Yolk sac tumor associated with the youngest age with a mean of 1.5 ± 0.5 years, (Table 5). However, the comparison of mean age of total 75 cases with germ cell tumor versus the 5 cases with non-germ cell tumor revealed no significant difference between both groups where the mean age was 32.7 ± 14.9 vs. 34.4 ± 14.4 years, respectively, (P. value > 0.05), (Table 6). Germ cell neoplasia in situ (GCNIS) was seen in 5 out of 75 cases with germ cell tumors (6.6%). Four of them (5.3%) were identified in the same testis harboring an invasive germ cell malignancy and one (1.3%) was seen in the contralateral testicle. None of them were associated with cryptorchidism. The histological subtypes of the associated invasive tumors were seminoma in 2 cases & mixed germ cell tumors with admixed seminoma in the other 3 cases. A history of cryptorchidism was recorded in three patients (3.75%). Two of them developed seminomas. The other patient had mixed germ cell tumors with admixed seminoma.

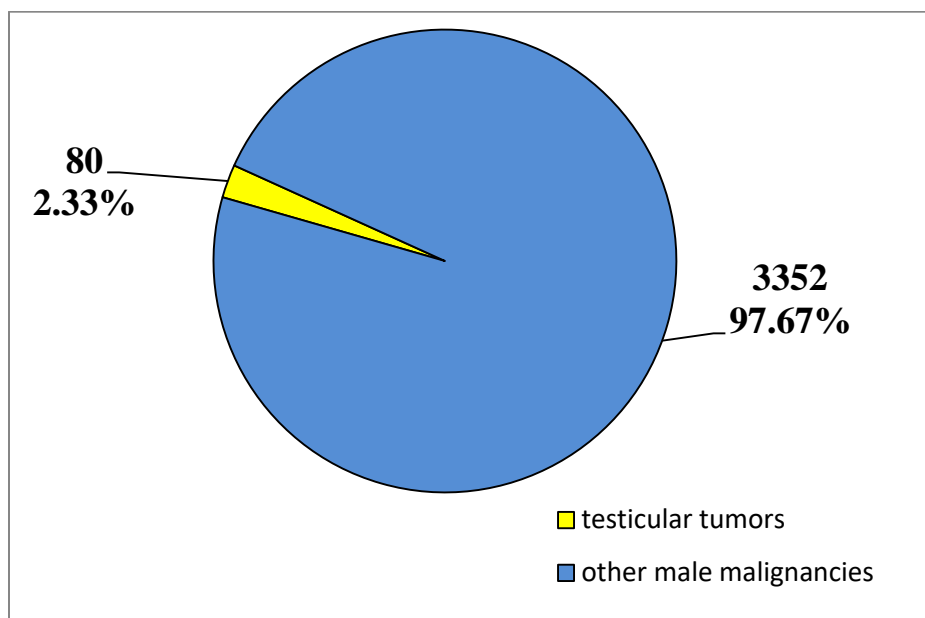


Figure 1. Distribution of total testicular tumors out of total malignancies in males for period 2005-2020

Table 1. Annual distribution of tumors registered during the period 2005 – 2020 and the rates of testicular tumors

Years	Total no. of cases	Malignancies in Males		Testicular tumors	
		No.	%	No.	%
2005	915	21	2.30	1	4.76
2006	1351	66	4.89	4	6.06
2007	1179	79	6.70	1	1.27
2008	845	39	4.62	2	5.13
2009	1015	75	7.39	4	5.33
2010	1289	89	6.90	1	1.12
2011	1784	115	6.45	4	3.48
2012	2297	156	6.79	4	2.56
2013	2537	254	10.01	4	1.57
2014	2792	287	10.28	4	1.39
2015	2956	287	9.71	7	2.44
2016	3496	330	9.44	13	3.94
2017	4119	403	9.78	4	0.99
2018	4783	451	9.43	7	1.55
2019	5220	394	7.55	8	2.03
2020	4221	386	9.14	12	3.11
Total	40799	3432	8.41	80	2.33
Average annual rate					2.92
P. value = 0.112 , no significant difference in the annual rates					

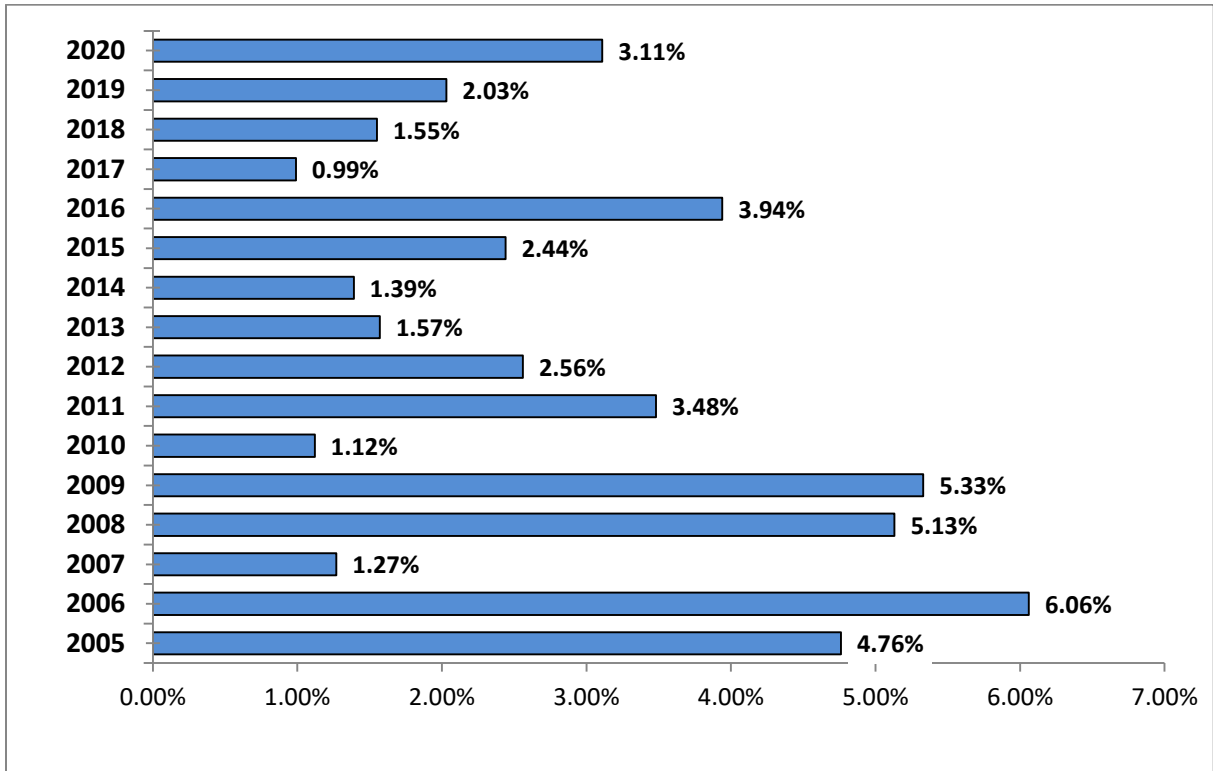


Figure 2. Distribution of Annual reported testicular tumors for the period 2005-2020

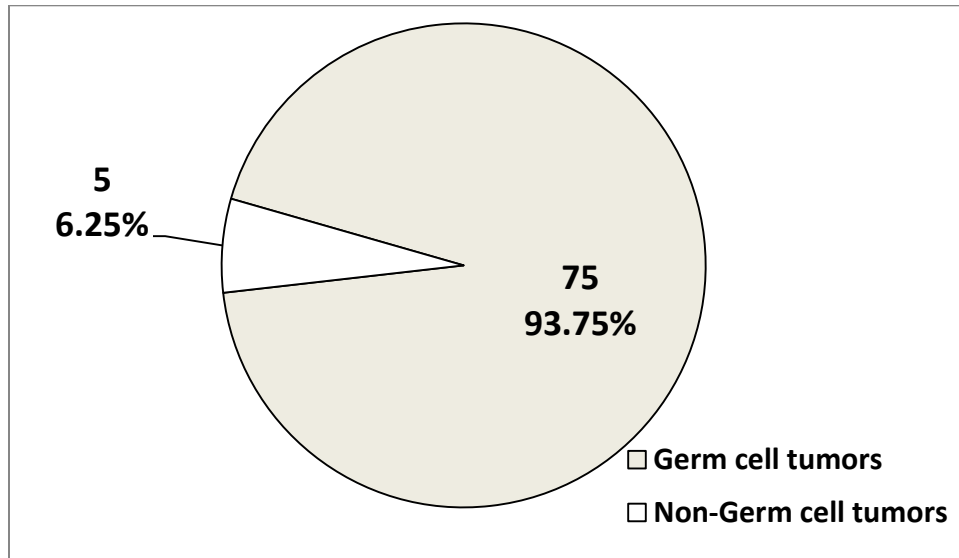


Figure 3. Types of total testicular tumors reported during period 2005-2020 (highly significant difference (P . value <0.001))

Table 2. Subtyping of 80 testicular tumors reported during period 2005-2020

Type of tumor		No.	%	
Germ cell tumors	Seminoma	34	42.5	
	Non-seminoma	YST	5	6.25
		Teratoma	3	3.75
		TSTM	1	1.25
		MGCT	31	38.75
	Sepermatocytic seminoma	1	1.25	
	Total	75	93.75	
Non-Germ cell tumors	Leydig cell tumor	1	1.25	
	NHL	2	2.50	
	Leukemic infiltration	2	2.50	
	Total	5	6.25	
Total		80	100.0	
YST: yolk sac tumor, TSTM: teratoma with somatic type malignancy, MGCT: mixed germ cell tumor, NHL: non-Hodgkin lymphoma.				

Table 3. Distribution of the 80 testicular tumors reported during the period 2005-2020 according to the affected side

Side	No.	%
Right	47	58.75%
Left	28	35.0%
Bilateral	1	1.25%
unavailable	4	5.0%
Total	80	100.0
P. value = 0.001 , significant more frequent right sided tumor		

Table 4. Bivariate Correlation matrix among the studied variables of testicular tumor cases

Variable	Statistics	Variable		
		Age	Histological type	Annual rate
Histological type	<i>R</i>	0.435		
	<i>P. value</i>	<0.001		
Annual rate	<i>R</i>	0.056	-0.039	
	<i>P. value</i>	0.619	0.729	
Side	<i>R</i>	-0.214	0.072	0.132
	<i>P. value</i>	0.057	0.525	0.243
R: Correlation Coefficient				

Table 5. Comparison of mean age of patients according to Histological type using ANOVA test

Histological type	No. of cases	Age (year)	
		mean	SD
Spermatocytic seminoma	1	75.0	0.0
Leydig cell tumor	1	50.0	0.0
NHL	2	41.0	5.7
Seminoma	34	39.7	11.0
Mixed germ cell tumor	31	30.5	9.3
Leukemic infiltration	2	20.0	7.1
Teratoma	3	19.5	15.9
Teratoma with somatic type malignancy	1	16.0	0.0
Yolk sac tumor	5	1.5	0.5

Table 6. Comparison of mean age of cases with germ cell tumor versus non-germ cell tumor

Histological type	No. of cases	Age (year)	
		mean	SD
Germ Cell tumor	75	32.7	14.9
Non-Germ Cell tumor	5	34.4	14.4
Total	80	32.8	14.7
P. value = 0.807, Not significant			

4. DISCUSSION

As mentioned previously, testicular tumor is relatively rare worldwide with the highest incidence being registered in western world compared to Asia and Arica(10). In this study, it represents 2.33% of all male malignancies which is slightly higher than the reported percentages (0.9% of all malignancies & 0.8% of male malignancies) in Tanzania & Pakistan respectively throughout 10 years period (11),(12). In a another study, the age- standardized rate of testicular cancer among Iranian males was 1.13(13). Although The annual distribution of the 80 cases was variable ranging between 0.99% in the year 2017 to 6.06% in the year 2006, but the statistical analysis revealed insignificant difference (P. value = 0.112). Histologically, Germ cell tumor was the most common subtype contributed for (93.75%), with seminoma accounting for (42.50%) , followed by MGCT (38.75%). Relatively, similar distribution of histological types was also seen in Lebanon(14) , Australia(15) and Germany(16). The non-germ cell tumors represented 6.25% and lies within the reported range in the united states (5-10%)(17).

The mean ages of patients diagnosed with testicular malignancies in general and those with germ cell tumors were 33 years. This is similar to the published statistics of the united states(18), Lebanon(14)and Germany(16) while in one study in Saudi Arabia the mean age for testicular tumors was 38.2(19). Patients diagnosed with seminoma had a mean age of 40 years (standard deviation of 11 years) while those diagnosed with non-seminomas had a mean age of 26 years (standard deviation of 13 years). This mean

age is compatible with a German literature, in which the mean ages of seminomatous vs non-seminomatous were 41 years vs 31 years respectively(20). Spermatocytic seminoma is usually consider a germ cell tumor of elderly although it has been recorded in younger patients with a mean age of (53.5years) ranging between (19 to 92 years)(21). In our study, a patient with Spermatocytic seminoma was the oldest one (75 years) representing (1.25%) of all testicular tumors , followed by patient with Leydig cell tumor (50 years,1.25%) then two patients with NHL (41 ± 5.7 years,2.5%) .it has been published that Leydig cell tumors constitute (2-3%) of testicular neoplasm and 80% of cases are diagnosed in young or middle age patients (30-60years) while NHL accounts for 5% of testicular malignancies being the most frequent subtype in patient over 60 years(22).

Yolk sac tumor was associated with the youngest age with a mean of 1.5 ± 0.5 years which is compatible with presenting age of prepubertat type in the literatures(23). However, the comparison of mean age of the total 75 cases with germ cell tumor versus the 5 cases with non-germ cell tumor revealed no significant difference between both groups where the mean age was 32.7 ± 14.9 vs. 34.4 ± 14.4 years, respectively, (P. value > 0.05). Regarding the side of tumors, right sided testicular malignancies were significantly the more frequent , 47/80 (58.75%), left sided ones represented (35%) and only one case with bilateral tumors. The right testis is more commonly affected by the neoplastic process in many reports from Tanzania (67.9%)(11), Japan(51.3%)(24), Pakistan (54.3%)(25) and Lebanon (55%)(14). A possible explanation is the higher frequency of the right sided undescended testis than on the left side(26). On other hand, Cryptorchidism is a strong risk factor for germ cell tumors and thought to have a role in (10%)(27) of cases and shown to the increase the risk of malignant transformation by four-folds(28). In this study it was recorded in three patients (3.75%). Two of them developed seminoma which is the most frequent reported subtype of germ cell tumors developed in crytorchid testis(29). The other patient had mixed germ cell tumors with admixed seminoma. This lower percentage of undescended testes could be attributed to lack of some clinical data about cases analyzed in our study.

Germ cell neoplasia in situ (GCNIS) is the well identified precursor lesion for most subtypes of testicular germ cell tumors and its prevalence among males was reported as

(0.4-0.8%) with the expectance that 70% of patients harboring GCNIS will develop related invasive germ cell tumor within 7 years (30). In our study, GCNIS was seen in 5 out of 75 cases with germ cell tumors (6.6%). Four of them (5.3%) were identified in the same testis harboring an invasive germ cell malignancy and one (1.3%) was seen in the contralateral normally appearing testicle which could be explained by the fact that unilateral testicular malignancy is strong risk factor for developing malignant growth on the other side(31) . However, in other studies GCNIS was reported quite more frequent than our work and assumed to been seen in (80-100%) of seminomatous and non seminomatous germ cell tumors and (5%) of the contralateral testis of germ cell tumors. This underestimation of GCNIS may be attributed to the loss of prognostic value of reporting it(32).Although cryptorchidism is a known risk factor for GCNIS(30,31), None of the 5 cases were associated with undescended testis. The histological subtypes of the associated invasive tumors were seminoma in 2 cases & mixed germ cell tumors with admixed seminoma in the other 3 cases which are GCNIS related subtypes of germ cell tumors(6).

5. CONCLUSIONS

This study shows that testicular tumors are relatively uncommon diagnoses in our lab at Alnajaf city. They are more likely to be a disease of young patient and the vast majority of cases are germ cell tumors (93.75%). Among them, seminoma predominates over non-seminomatous germ cell tumors while mixed germ cell tumor is the most frequent form in the latter. The right testicle is more commonly affected by the neoplastic process as compared to the left side. Cryptorchidism is reported as a risk factor in 3.75% of cases while GCNIS is reported in only 6.6% cases of germ cell tumor which is quite lower than the reported percentage globally.

Ethical Clearance: Ethical clearance and approval of the study are ascertained by the authors. All ethical issues and data collection were in accordance with the World Medical Association Declaration of Helsinki 2013 of ethical principles for medical research involving human subjects. Data and privacy of patients were kept confidentially.

Conflict of interest: Authors declared none

Funding: None, self-funded by the authors

References

1. world health organization, international agency for research on cancer, fact sheets on cancers , globocan : testis, 2020. Available at : <https://gco.iarc.fr/today/data/factsheets/cancers/28-Testis-fact-sheet.pdf>, accessed September 2021.
2. Ghazarian AA, Kelly SP, Altekruse SF, Rosenberg PS, McGlynn KA. Future of testicular germ cell tumor incidence in the United States: Forecast through 2026. *Cancer*. 2017 Jun 15;123(12):2320-8.
3. Shanmugalingam T, Soultati A, Chowdhury S, Rudman S, Van Hemelrijck M. Global incidence and outcome of testicular cancer. *Clinical epidemiology*. 2013;5:417-27.
4. world health organization, international agency for research on cancer, fact sheets on cancers , globocan : Iraq, 2020. Available at : <https://gco.iarc.fr/today/data/factsheets/populations/368-iraq-fact-sheets.pdf>, accessed September 2021.
5. Yamashita S, Koyama J, Goto T, Fujii S, Yamada S, Kawasaki Y, Kawamorita N, Mitsuzuka K, Arai Y, Ito A. Trends in Age and Histology of Testicular Cancer from 1980-2019: A Single-Center Study. *The Tohoku Journal of Experimental Medicine*. 2020;252(3):219-24.
6. Tumours of the testis and paratesticular tissue. In: Moch H, Humphrey PA, Ulbright TM, Reuter VE (Eds). *WHO classification of tumours of the urinary system and male genitals organs*. 4th ed. Lyon: International agency for research on cancer; 2016.
7. Al-Hussain T. Germ cell tumors-general. *PathologyOutlines.com website*. <https://www.pathologyoutlines.com/topic/testisgctgeneral.html>. Accessed October 31st, 2021.
8. McKenney JK. Testis and testicular adnexa. In: Goldblum JR, Lamps LW, McKenney JK, Myers JL (Eds). *rosai and ackerman's surgical pathology*. 11th ed. Philadelphia: Elsevier; 2018.
9. Sharma P, Dhillon J, Sexton WJ. Intratubular germ cell neoplasia of the testis, bilateral testicular cancer, and aberrant histologies. *Urologic Clinics*. 2015 Aug 1;42(3):277-85.
10. Gurney JK, Florio AA, Znaor A, Ferlay J, Laversanne M, Sarfati D, Bray F, McGlynn KA. International trends in the incidence of testicular cancer: lessons from 35 years and 41 countries. *European urology*. 2019 Nov 1;76(5):615-23.
11. Chalya PL, Simbila S, Rambau PF. Ten-year experience with testicular cancer at a tertiary care hospital in a resource-limited setting: a single centre experience in Tanzania. *World journal of surgical oncology*. 2014 Dec;12(1):1-8.
12. Iqbal J, Kehar SI, Jaffer N, Asad F. Frequency and morphological study of testicular germ cell tumor. *The Professional Medical Journal*. 2019 Oct 10;26(10):1794-8.
13. Hassanipour S, Ghorbani M, Derakhshan M, Fouladseresht H, Mohseni S, Abdzadeh E, Riahi S,

- Arab-Zozani M, Delam H, Salehiniya H. The incidence of testicular cancer in Iran from 1996 to 2017: A systematic review and meta-analysis. *Advances in Human Biology*. 2019;9(1):16-20.
14. Assi T, Rassy M, Nassereddine H, Sader-Ghorra C, Abadjian G, Ghosn M, Kattan J. Distribution of testicular tumors in Lebanon: a single institution overview. *Asian Pacific Journal of Cancer Prevention*. 2015;16(8):3443-6.
15. Baade P, Carriere P, Fritschi L. Trends in testicular germ cell cancer incidence in Australia. *Cancer Causes & Control*. 2008 Dec;19(10):1043-9.
16. Ruf CG, Isbarn H, Wagner W, Fisch M, Matthies C, Dieckmann KP. Changes in epidemiologic features of testicular germ cell cancer: age at diagnosis and relative frequency of seminoma are constantly and significantly increasing. *In Urologic Oncology: Seminars and Original Investigations* 2014; 32 (1): 33-e1.
17. Dilworth JP, Farrow GM, Oesterling JE. Non-germ cell tumors of testis. *Urology*. 1991 May 1;37(5):399-417.
18. American Cancer Society, About testicular cancer, Key Statistics for Testicular Cancer. Available from: <https://www.cancer.org/cancer/testicular-cancer/about/key-statistics>, accessed on February 2022.
19. Albasri AM, Hussainy AS. Histopathological pattern of testicular diseases in western Saudi Arabia. *Saudi Medical Journal*. 2018 May;39(5):476.
20. Dieckmann KP, Richter-Simonsen H, Kulejewski M, Ikogho R, Zecha H, Anheuser P, Pichlmeier U, Isbarn H. Testicular germ-cell tumours: a descriptive analysis of clinical characteristics at first presentation. *Urologia Internationalis*. 2018;100(4):409-19.
21. Carrière P, Baade P, Fritschi L. Population based incidence and age distribution of spermatocytic seminoma. *The Journal of urology*. 2007 Jul;178(1):125-8.
22. Bacon CM, Freeman A. Small cell tumors, lymphomas, and sertoli cell and leydig cell tumors of the bladder, prostate, and testis. *In Urological cancers 2005* (pp. 309-331). Springer, London.
23. Kattuo MI, Kumar A. Yolk Sac Tumors. [Updated 2022 Feb 7]. In: *StatPearls [Internet]*. Treasure Island (FL): StatPearls Publishing; 2022 Jan-. Available from: <https://www.ncbi.nlm.nih.gov/books/NBK563163/>
24. Miki T, Kamoi K, Fujimoto H, Kanayama HO, Ohyama C, Suzuki K, et al.. Clinical characteristics and oncological outcomes of testicular cancer patients registered in 2005 and 2008: The first large-scale study from the Cancer Registration Committee of the Japanese Urological Association. *International Journal of Urology*. 2014 Aug;21(8):S1-6.
25. Bhatti AB, Ahmed I, Ghauri RK, Saeed Q, Mir K. Clinical profile, treatment and survival outcome of testicular tumors: a Pakistani perspective. *Asian Pacific Journal of Cancer*

- Prevention*. 2014;15(1):277-80.
26. Leslie SW, Sajjad H, Villanueva CA. Cryptorchidism. [Updated 2021 Sep 17]. In: StatPearls [Internet]. Treasure Island (FL): StatPearls Publishing; 2022 Jan-. Available from: <https://www.ncbi.nlm.nih.gov/books/NBK470270/> accessed February 2022.
27. Mannuel HD, Mitikiri N, Khan M, Hussain A. Testicular germ cell tumors: biology and clinical update. *Current opinion in oncology*. 2012 May 1;24(3):266-71.
28. Banks K, Tuazon E, Berhane K, Koh CJ, De Filippo R, Chang A, Kim SS, Davis-Dao CA, Lewinger JP, Daneshmand S, Bernstein L. Cryptorchidism and testicular germ cell tumors: comprehensive meta-analysis reveals that association between these conditions diminished over time and is modified by clinical characteristics. *Frontiers in endocrinology*. 2013; 18;3:182.
29. Ferguson L, Agoulnik AI. Testicular cancer and cryptorchidism. *Frontiers in Endocrinology*. 2013 20;4:32.
30. Spiller CM, Bowles J. Germ cell neoplasia in situ: The precursor cell for invasive germ cell tumors of the testis. *The International Journal of Biochemistry & Cell Biology*. 2017 May 1;86:22-5.
31. Sharma P, Dhillon J, Sexton WJ. Intratubular germ cell neoplasia of the testis, bilateral testicular cancer, and aberrant histologies. *Urologic Clinics*. 2015 1;42(3):277-85.
32. Akyüz M, Topaktaş R, Ürkmez A, Koca O, Öztürk Mİ. Evaluation of germ-cell neoplasia in situ entity in testicular tumors. *Turkish Journal of Urology*. 2019 Nov;45(6):418-27.