



## Effect of Derotational Humeral Osteotomy on Function of Shoulder Joint in Cases with Erb's Palsy: A Clinical Evaluation and Outcome

Dr. Burair M.A. Alasadi<sup>1\*</sup>, Dr. Ihsan M.A. Faraj<sup>2</sup>, Haithem M. Alasedy

1,2,3 MBChB, M.D. - F.I.B.M.S. Ortho., Alhussain medical city /kerbala-Iraq

\*Corresponding Author , contact email :[burairalasadi@yahoo.com](mailto:burairalasadi@yahoo.com)

Original Article

### ABSTRACT

*Erb Duchenne's palsy is a paralysis of the upper extremity due to brachial plexus roots injury; C5 and C6, the injury or compression that occur during birth. Surgical or non-surgical treatment are both utilized. Derotating Osteotomy performed when conservative and neurosurgical measures failedn, it is extremely important to improve shoulder stability and mobility. It allows the arc of rotation to be displaced, in order to improve external rotation, both in internal rotation contractures (limitation of passive external rotation) and in the absence of donor muscles. Many advantages of this procedures have been reported. Therefore we aimed to evaluate and address the effects of derotational humeral osteotomy on shoulder function among group of Iraqi patients aged 6.5 to 25 years who were managed in our hospital in Karbala during 2018-2019. We concluded that derotational humeral osteotomy is good , safe option of treatment in Erb's palsy cases with internal rotation contractures and/or gleno-humeral joint deformity. Higher functional and aesthetic satisfaction rates were obtained. In this procedure, no need for intensive physical therapy which an advantage to facilitate the treatment of younger patients compared to soft tissue such as tendon transfer operations*

**Keywords:** *Erb's palsy, epidemiology, etiology, pathogenesis, treatment, osteotomy, Derotational Humeral Osteotomy*

**Article information:** Received: June 2021, Accepted and published online August 2021.

**How to cite this article:** Alasadi B, Faraj I, Alasedy A. Effect of Derotational Humeral Osteotomy on Function of Shoulder among Cases with Erb's Palsy: A Clinical Evaluation and Outcome, Journal of Medical and Surgical Practice (JMSP) 2021; 7(2):

## 1. INTRODUCTION

Erb's palsy is a paralysis of the upper extremity due to brachial plexus roots injury; C5 and C6, the injury or compression that occur during birth . Despite majority of patients have recovered spontaneously without intervention and their upper extremity function almost nearly normal, but some patients still have neurological deficit and malfunctioning (1–3) Historically, Duchenne de Boulonge coined the term obstetric paralysis in 1872 to a bilateral brachial paralysis of the newborn described years earlier. It was not until 1874, when Erb described the location of the lesion: C5-C6. In 1885, Klumpke described a similar paralysis for the lower plexus. Lesions associated with the upper brachial plexus are called Erb's palsy, and those associated with lower brachial plexus injury are called Klumpke's palsy (4–6).

Erb's palsy manifested by a loss of mobility of the arm with or without involvement of the forearm and hand, although the usual is affection of the entire limb. There are many risk factors associated with BPP including both maternal and neonatal factor in addition to labor conditions; these lesions appear in newborns, as a consequence of inexperienced maneuvers in the assistance of difficult deliveries such as macrosomic (large) children, breech deliveries , Shoulder dystocia, prolonged 2nd stage labor, etc. The characteristic position is adduction (active or passive movement that brings a limb or an organ closer to the median plane of the body) with pronation (internal rotation) of the arm and forearm; the extension power of the forearm is preserved, but not the arm. With the improvement in obstetric care, the incidence of these paralyzes has decreased significantly. Its overall incidence ranges from 0.2-0.4% of all live births (4,7). Incidence of OBPP range between 0.15 to 3 per 1000 live births in different series and countries. In countries in which obstetrical care is poor, obstetrical brachial plexus palsy is noted more frequently (8). Up to 10% of obstetric brachial plexus palsy are bilateral, seen almost exclusively in breech presentations (9). In almost 47% of OBPP cases, the upper trunk is involved at C5-C6 roots which is known as Erb's Palsy. However, sometime, the whole BP involved (C5-T1) in about 24% of cases which is known as total (global) OBPP(9).

### ***Pathogenesis***

As a result of the injury, there may be neuropraxia, a rupture, tearing, tension of the trunks of the brachial plexus and avulsion from the spinal cord, as well as possible bleeding. After some time in the area of the nerve plexus of the humerus, a scar is formed, which causes re-

compression of the plexus. This develops nerve conduction, which threatens such consequences as circulatory disorders and the formation of neuroma inside the trunk (10,11).

***Clinical features:***

The manifestations of paralysis are clearly visible , the newborn, has decreased spontaneous movement and asymmetrical infantile reflexes . The clinical presentation of the injury at the time of delivery can be subtle, but the days following it, it can begin to be noticed: an internally rotated and pronated arm without movement of the shoulder, elbow, hand, and wrist flexion. With complete brachial plexus paralysis, the entire arm and hand are deprived of movement (4,5,9,12).

***Diagnosis :***

Mainly based on clinical evaluation, however, further investigations and tests assist to exclude other conditions, nerve conduction study, Electromyography, Computed Tomography, myelography and MRI as well as intraoperative somatosensory-evoked potentials , all been used to measure and provide images of damage to the neonatal brachial plexus, with the goal of differentiating non repairable preganglionic rupture from postganglionic injury, which may be repairable or may recover without surgical intervention (13–16).

***Treatment***

Surgical or non-surgical treatment of OBPP are both utilized, the main goal of treatment is to prevent contractures formation during recovery, to restore neurological functions, to augment weak muscles, and to manage deformities ,as much as possible, due to imbalance of muscles. Tactics to combat paralysis is determined by the specific clinical case. Conservative and surgical techniques can be used to completely or partially eliminate its consequences. Treatment of obstetric paralysis has always lasted and requires some endurance from parents and the child - it lasts for months. At first attempts are made to correct the situation by means of conservative methods: immobilization of the injured hand with a special splint; medications , therapeutic gymnastics; massage courses; physiotherapy. The effectiveness of conservative therapy is determined by the integrity of nerve fibers. To succeed, at least part of them must remain intact. The effect is determined after 3 months. If up to three years of age the baby cannot actively bend the elbow, the experts consider the feasibility of surgery (1,6,13,17).

### ***Surgical treatment***

include microsurgery , tendon transfer, and Osteotomy. In microsurgery, suturing of nerve fibers and plasticity of the nerve trunk is performed. Observations show that more effective are those operations that were performed in the period of 3-7 months of life. Even if the operation is successful, it solves only some of the problems. After that, the child is prescribed a long course of rehabilitation, consisting of medication and physiotherapy. It aims to maximize the recovery of all lost functions (1,6,13,17).

### ***Derotational Osteotomy:***

In OBPP, after all conservative and neurosurgical measures have been taken, it is extremely important to improve shoulder stability and mobility. In this regard, there are various muscle transposition operations, in addition to shoulder arthrodesis, that can be performed in the treatment of paresis of the deltoid and supraspinatus muscles. The teres major and latissimus dorsi muscles cannot always be used as donor muscles in a transposition 25 (in about 60% of cases they present a degree of force between 0 and 2) However, the derotating osteotomy of the humerus allows the arc of rotation to be displaced, in order to improve external rotation, both in internal rotation contractures (limitation of passive external rotation) and in the absence of donor muscles. Surgical principles and objectives. An osteotomy of the medial third of the humerus and an external rotation of 30° to 60° of the distal portion of the humerus are performed. Stabilization is achieved by plate osteosynthesis. In this way, the arc of rotation is displaced to allow external rotation so that, once the intervention has been carried out, physiological flexion of the elbow is achieved without the forearm hitting the thorax or producing a compensatory abduction and ante version movement. in the shoulder (18–21).

### ***Complications of Humeral osteotomy:***

Malunion, improper rotational correction, concomitant abduction contracture failure, scar formation (hypertrophic) . Non-union is rare. Although suboptimal functional gain due to under correction may occur, it is important to avoid excessive external rotation of distal humeral segment. However, significant limitation in personal hygiene may results due to inability to locate the ipsi-lateral hand on the mouth, chest or perineum also it may interfere with daily activities, and quality of life of the patients. Bimanual tasks may also affected even in cases with subtle overcorrection. Patients should be informed and instructed about the possibility of formation of hypertrophic scar formation despite careful skin incisions.

However, in cases with persistent scars, revision could be diverted to improve aesthetic appearance. Additionally, as in many surgeries, infection is not uncommon in this intervention. Also fractures could occur in the site close to the implant, specially, in active younger patients (13,18,21,22)

## **2. PATIENTS and METHODS**

A prospective study conducted during a period of 18 months (2018-2019) at our hospital. Included a total of 40 cases (21 males and 19 females) with proved diagnosed brachial plexus birth palsy treated with derotational osteotomy of humerus. All patients had Erb's palsy and had been treated after birth with physiotherapy for a period of 6-12 months with residual deformity. None of the patients had primary brachial plexus exploration or tendon transfer previously. Patients who are less than 5 years of age, improving on physiotherapy or those who are candidates for other mode of treatment and those with complete palsy were excluded from the study. Preoperatively, we assessed the ability of the patients to perform daily activities (feeding, washing, and grooming themselves) with the affected upper extremity. The active and passive ranges of motion of the entire upper extremity were assessed. None of the affected arms could be externally rotated either actively or passively beyond neutral.

All patients had a fixed internal rotation deformity ranging from 20 to 50 degrees (mean 40°). Active abduction of the arm ranged from 30 to 160 degrees (mean shoulder abduction, 135°), Passive abduction was 10 to 40 degrees greater than active abduction, especially if the arm was held in the coronal plane. Active internal rotation of the arm was 20 to 50 degrees (mean 40°), passive internal rotation was 10 to 15 degrees greater than active internal rotation. The modified Mallet classification system was used to assess the function of the shoulder. Sixteen patients had a modified Mallet grade 3 and fourteen patients had grade 4 regarding global abduction. All patients had grade 2 regarding global external rotation, hand to neck and hand to mouth parameters. Regarding hand to spine parameter, 20 patients had grade 2 and 20 patients had grade 3. In all patients, the hand reached the mouth with a trumpet sign (the shoulder is abducted as in blowing a trumpet), and upon reaching the mouth the dorsum of the hand was uppermost. Other preoperative motion limitations include slight (15° to 25°; mean 20°) deficit of elbow extension in 16 patients (secondary to mild

elbow flexion contracture), and slight forearm pronation with lack of active supination. Elbow flexion and wrist and digital motions were normal before surgery in all children. Plain X-rays were taken for all patients and shoulder deformity was assessed using the grading system of Al-Qattan (2009) (23). All patients had mild to moderate changes (score 5 to 7) in gleno humeral joint; flattening of humeral head and/or shallow glenoid. CT scan and MRI were not performed as our selection of patients for humeral osteotomy was based mainly on clinical basis (presence of fixed internal rotation contracture in all patients with a mean age of 9.45 years) in addition to plane X-rays assessment. We did not perform arthrography or electro diagnostic studies for any patient

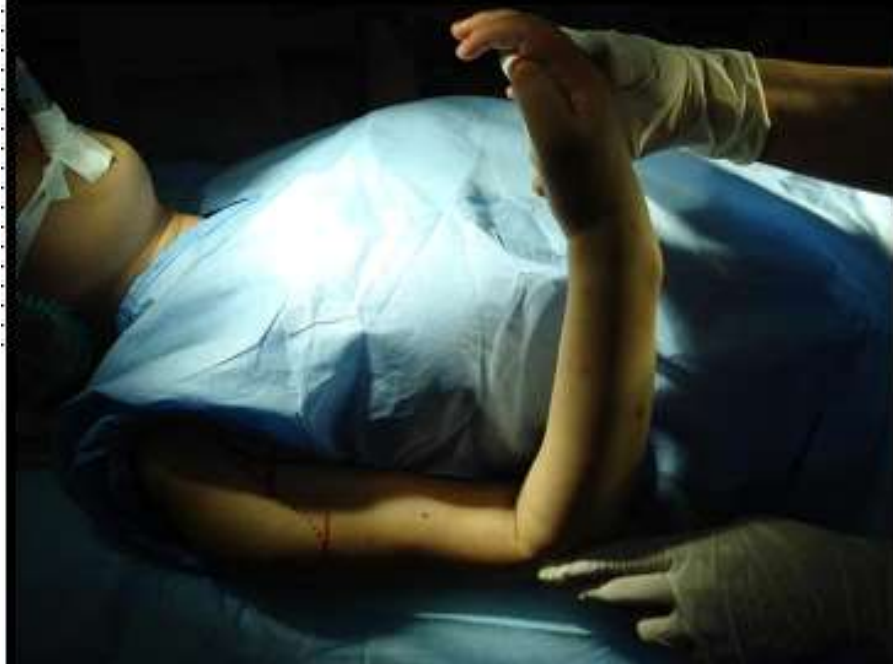### ***Operative technique***

The operation was performed with the patient under general anesthesia and in the supine position. A sandbag was placed under the involved shoulder. It is recommended that the face, midline of the body and groin be marked or easily palpated beneath the surgical drapes to allow for intra-operative evaluation of the rotational correction. Antibiotics are given peroperatively for prophylaxis against infection (Ceftriaxone vial 0.5 gram for patients younger than 10 years and 1 gram vial for patients older than 10 years). Examination under anesthesia is recommended to assess the degree of internal rotation contracture. With the scapula stabilized, external rotation is assessed both with the arm adducted against the side of the body (**Figure 1**) and with the shoulder abducted 90 degrees. These observations will guide the amount of external rotation desired from the ensuing osteotomy. The humerus was exposed via a deltopectoral approach, centered at the level of the deltoid insertion. Gently curved incisions extending from proximal-lateral to distal medial are used in anticipation of the subsequent external rotation of the distal limb; this will allow for a linear skin closure and will help minimize hypertrophic scar formation resulting from excessive skin tension. After the deltopectoral interval is developed, the periosteum is longitudinally incised, and careful subperiosteal exposure of the humerus is achieved. Great care is made to stay subperiosteal and minimize trauma to the posterior soft tissues in efforts to avoid iatrogenic radial nerve injury. A transverse osteotomy is planned at the level just proximal to the deltoid insertion. The level is marked and an appropriately sized plate is placed over the humerus. Size and length of the plate are chosen based upon the size and age of the patient; one third tubular or single 3.5-mm dynamic compression plates may be used in younger and

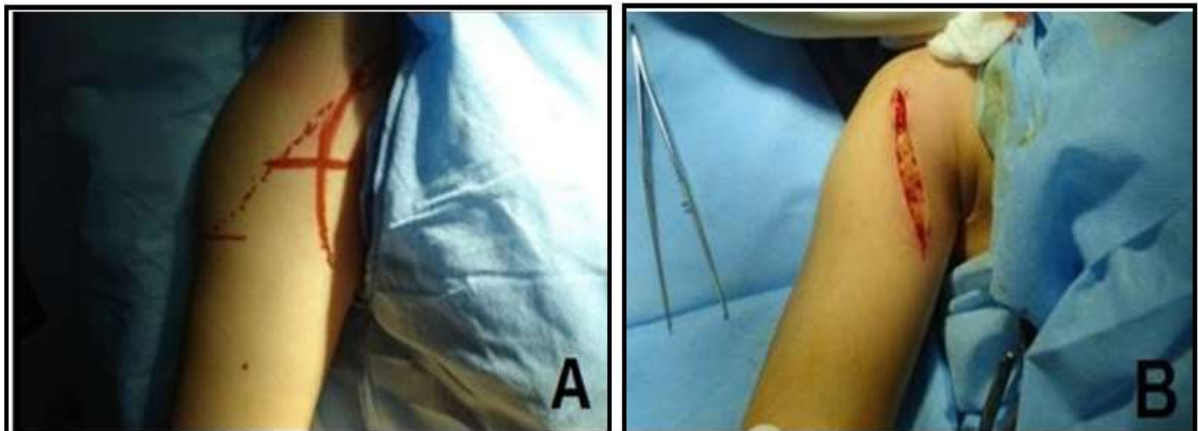
older patients, respectively. The proximal holes in the plate are then drilled at the appropriate locations, and the holes are measured and tapped. We use the monopolar electro cautery to mark the humeral cortex along the edge of the plate proximal and distal to the planned osteotomy site. These markings will assist in evaluating the amount of rotation achieved later in the procedure . Alternatively, smooth Kirschner wires may be drilled into the humerus in a parallel fashion above and below the plate and used to measure subsequent rotation. A transverse osteotomy is then performed with a small oscillating blade, just proximal to the level of the deltoid insertion. A number of technical points are worthy of note. First, continuous irrigation of the humerus and saw blade should be performed during osteotomy to avoid thermal necrosis, which may inhibit bony healing. Furthermore, great care should be taken to ensure that the osteotomy is perpendicular to the long axis of the humerus; if an oblique cut is made, there will be oblique angulation of the humerus with rotation of the distal fragment. Finally, low profile retractors should be placed subperiosteally and posterior to the humerus to protect the adjacent soft tissues and radial nerve. Upon completion of the transverse osteotomy, the distal fragment is externally rotated to allow for improved positioning of the hand away from the body and overhead. Typically, 30 degrees to 90 degrees of external rotation is desirable, and the previously placed K-wires or humeral markings may be used to guide rotation. The plate may be applied at this time to the proximal segment through the previously drilled screw holes to allow for better control of the proximal humerus during rotation. Before the placement of distal fixation, intraoperative assessment of the degree of rotation is performed. Care is made to ascertain that the ipsilateral hand can be easily placed on the mouth, occiput, and midline in efforts to avoid overcorrection. Once the desired amount of rotation is achieved, the distal screws are placed and rigid internal fixation achieved by using plate and screws (4-6 screws). (Figure 2-6). The periosteum is reapproximated over the plate using multiple interrupted absorbable sutures. Subcutaneous tissues are closed in layers after insertion of radiovac suction drain and skin closed with a running subcuticular stitch or interrupted suturing postoperatively, patients are immobilized in a sling and Swathe. Immobilization is typically discontinued 4 to 6 weeks postoperatively after radiographic confirmation of bony union. Patients subsequently begin physical therapy for range of motion and strengthening exercises (**Figures 2,3 & 4**)

***Statistical analysis and data management:***

All performed using the statistical package for social sciences version 24 for windows, data presented as frequencies, percentage, mean and standard deviation according to the type of variables, statistical tests and procedures applied accordingly at a level of significance of  $\leq 0.05$

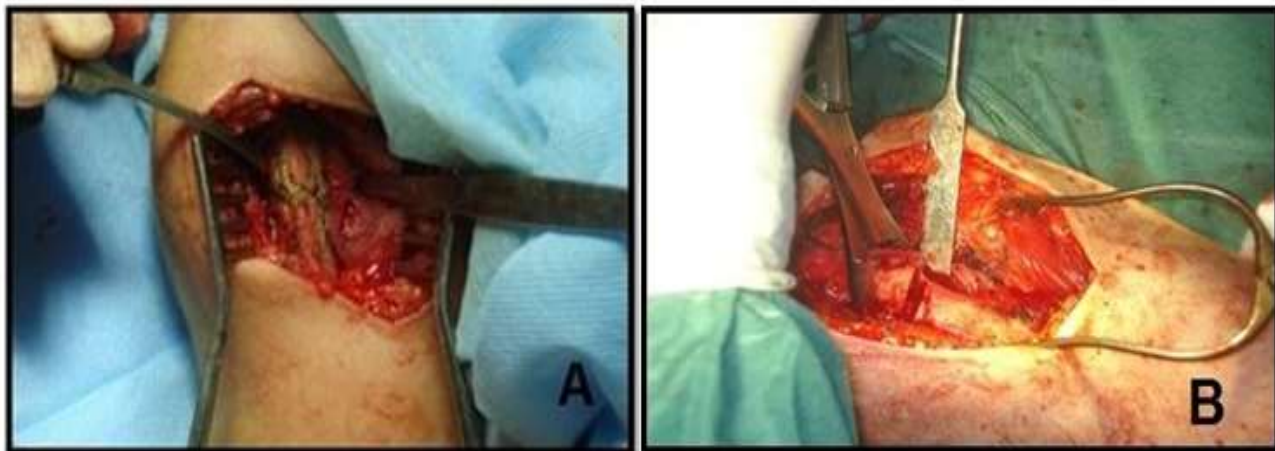


***Figure 1. Intra-operative assessment of shoulder external rotation***

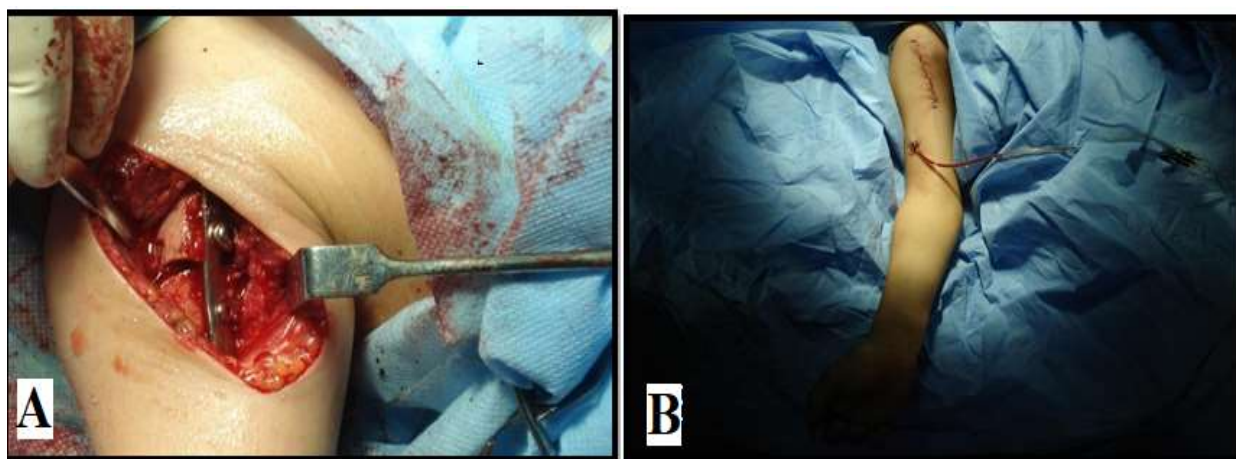


***Figure 2. A: planning for skin incision B: skin incision***





*Figure 3. A. Marking the osteotomy site B. Osteotomy done*



*Figure 4. A: Fixation with plate and screws , B: Wound closure over a radivac drain*

### 3. RESULTS

A total of 40 patients were enrolled in this study with a mean age of  $9.5 \pm 2.8$  (range: 6.5 – 25) years. Males were 21 (52.5%), right sided Erb's palsy reported in 60% of cases (**Table 1**). At final follow-up examination, the mean shoulder external rotation was  $45^\circ$  (range,  $30^\circ$  to  $60^\circ$ ). The postoperative modified Mallet score is improved; all patients had a grade 4 ( in all parameters of Mallet system except for global shoulder abduction and hand to spine parameters which were not changed). The hand reached the mouth in a better functional position: there was no trumpet sign and the palm, rather than the dorsum, was facing the mouth. The humeral osteotomy procedure did not result in improved active forearm

supination; however, with active supination of the forearm the palm will reach the mouth regardless of shoulder position. Therefore, the reason for the improved hand position when reaching the mouth was the correction of the internal rotation contracture of the shoulder that resulted in elimination of excessive shoulder abduction when reaching the mouth.

All cases could dress, wash, perform general self-cleaning, and feed themselves better and no longer needed help with these activities. An extra bonus of the osteotomy procedure was slight improvement of elbow flexion contracture in all cases who have this deformity (postoperative elbow extension deficit, 10° to 15° with mean of 13°). There is no change in active range of abduction postoperatively as compared with preoperative range of motion. Shoulder internal rotation range of movement was improved slightly postoperatively as compared with preoperative assessment, (**Tables 2 & 3**). We asked the patients and parents to put their satisfaction regarding the results of the operation in one of 4 levels (excellent, good, fair, and poor), the excellent and good satisfaction was 86.5 %, fair satisfaction was 12.5% , while none reported poor satisfaction (**Tables 4**). Unfortunately, some complications have been developed among patients, two patients had post-op infection , treated by antibiotics and removal of hardware with revision of fixation later on. Fracture of humerus and loss of fixation in one patient, and Hypertrophic scar in 5 patients, (**Tables 5**). Additionally, some photos are inserted below for some of our patients demonstrated pre and postoperative findings and outcome of surgery (**Figures 5 – 10**).

**Table 1. Distribution Baseline characteristics of the studied group (N=40)**

Variable		Values
Age (year)	Mean	9.5
	SD	2.8
	Range	6.5 - 25
Gender	Male , n (%)	21 (52.5)
	Female , n (%)	19 (47.5)
Side	Right	24 (60.0)
	Left	16 (40.0)

**Table 2. Various joint movements (mean, range of movement in degrees) before the osteotomy and compared with postoperative results**

Joint	Movement tested	Pre-operative	Post-operative
Shoulder	Abduction	135 (30–160)	135 (30-160)
	External rotation	Less than 0 in all patients	45 (30 - 60)
	Internal rotation	40 (20-50)	50 (0 - 70)
Elbow	Extension deficit 16	20 (15-25)	13 (10 - 15)

**Table 3. Modified mallet grading system pre-, and postoperatively in 40 cases who underwent humeral osteotomy**

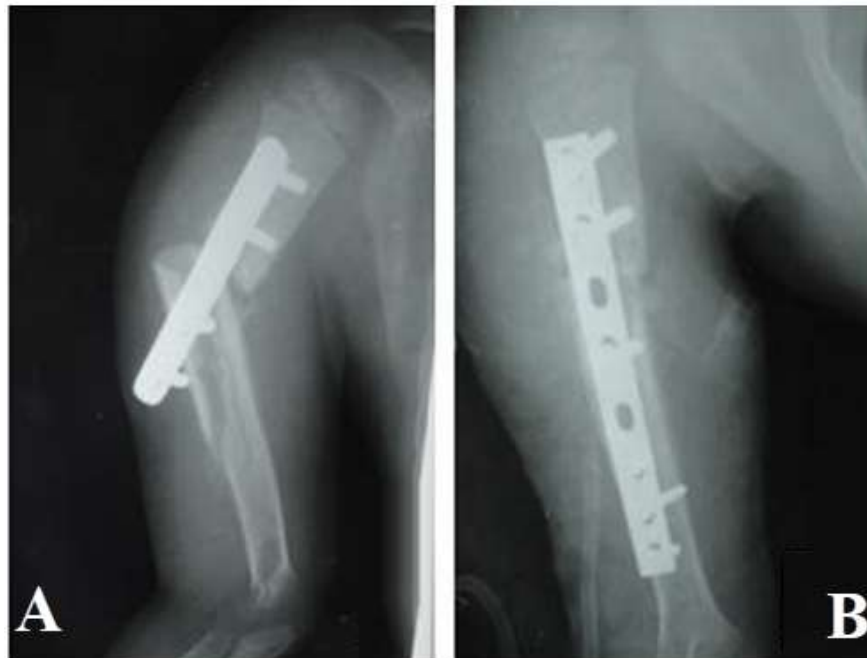Modified mallet grading system	Pre-operative	Post-operative
Global abduction	Grade 3 in 21 patients Grade 4 in 19 patients	Not changed
Global external rotation, hand to neck, hand to mouth	Grade 2 in all patients	Grade 4 in all patients
Hand to spine	Grade 2 in 20 patients Grade 3 in 20 patients	Not changed

**Table 4. The patients and/or parents satisfaction regarding the results of operation**

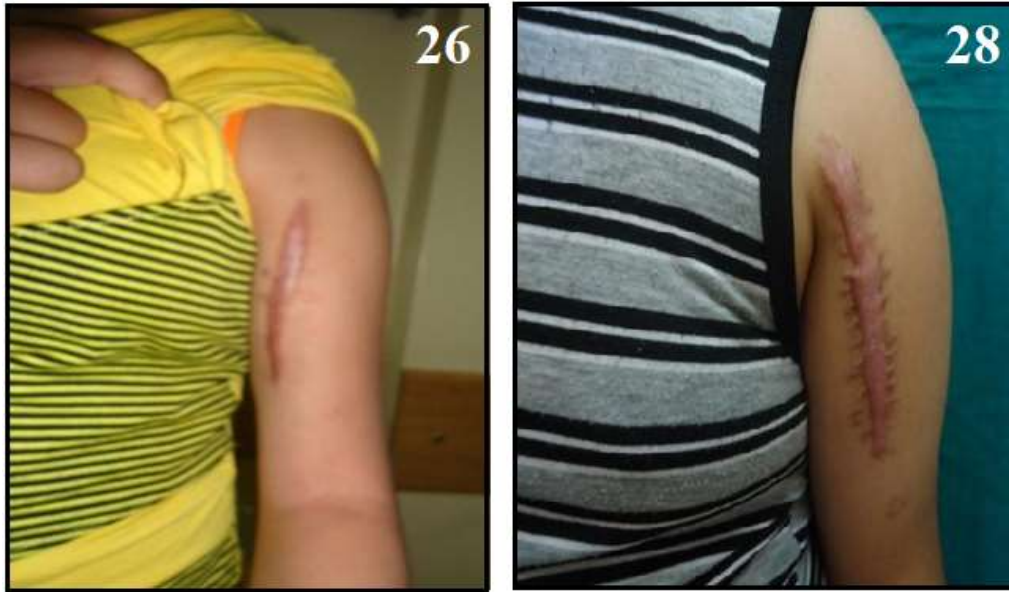Level of satisfaction	Number of patients/parents	%
Excellent	7	17.5
Good	28	70.0
Fair	5	12.5
Poor	0	0.0
Total	40	100.0

**Table 5. The complications of surgery**

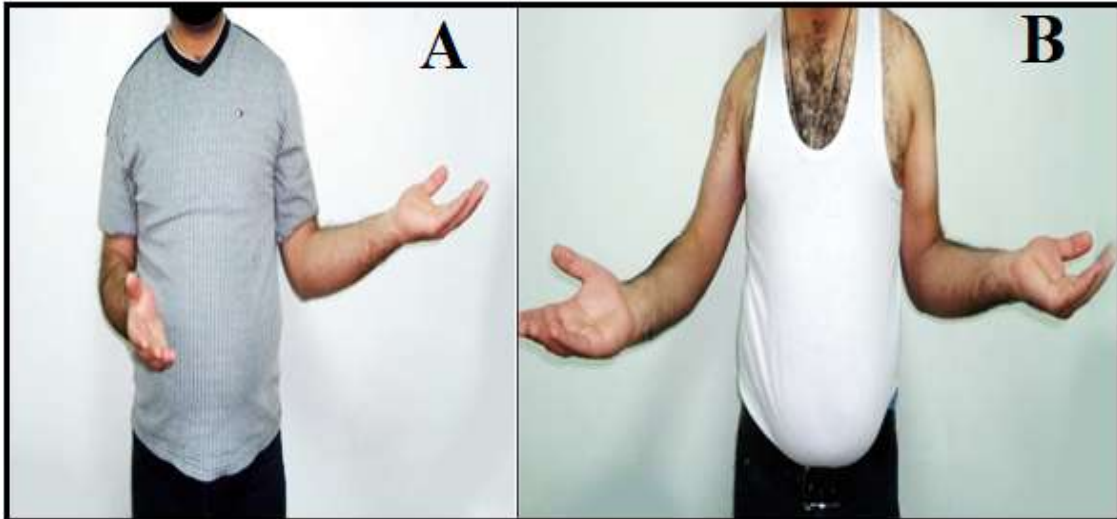
Complication	No. of patient	percentage
Post-op. infection	2	5.0
Fracture of humerus and loss of fixation	1	2.5
Hypertrophic scar	5	12.5
Total complication	8	20.0



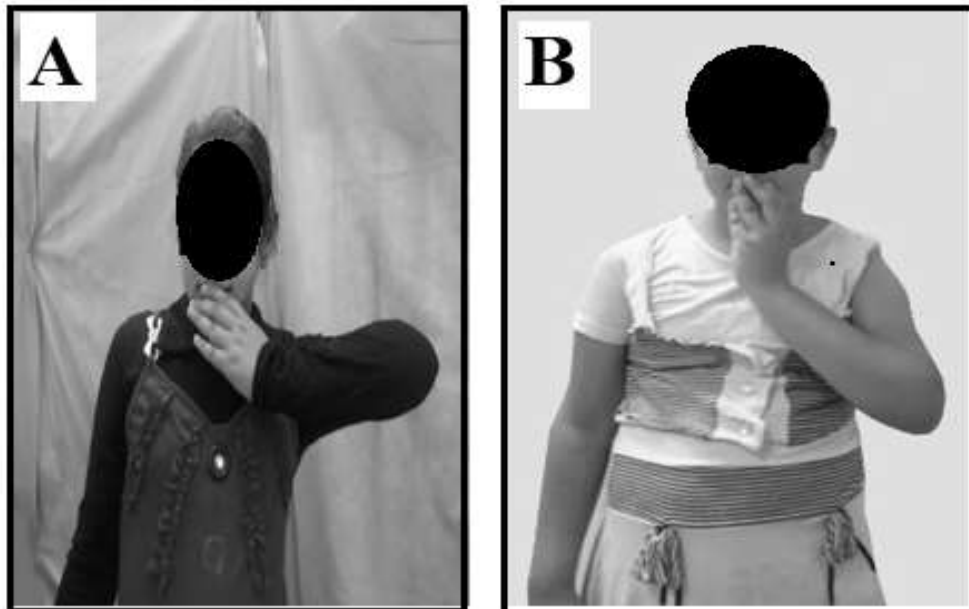
**Figure 5. Patient No.13 in our study A- Fracture distal to osteotomy site with loss of fixation. B- Revision surgery**



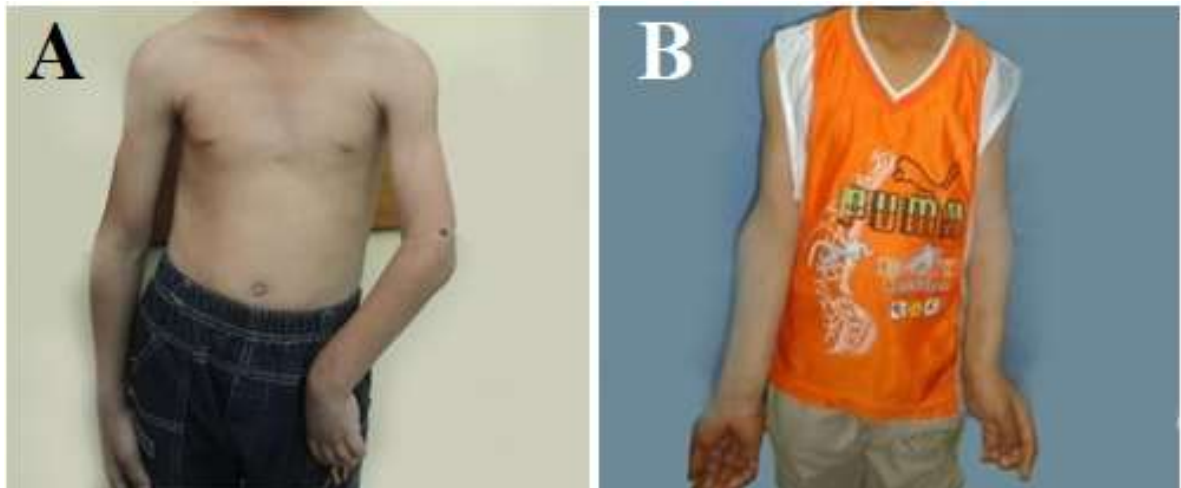*Figure 6. Two patients in our study( patient No.26 and No. 28) with hypertrophic Scars.*



*Figure 7. Improvement of shoulder external rotation (A. Pre-op. ; B post-op.)*

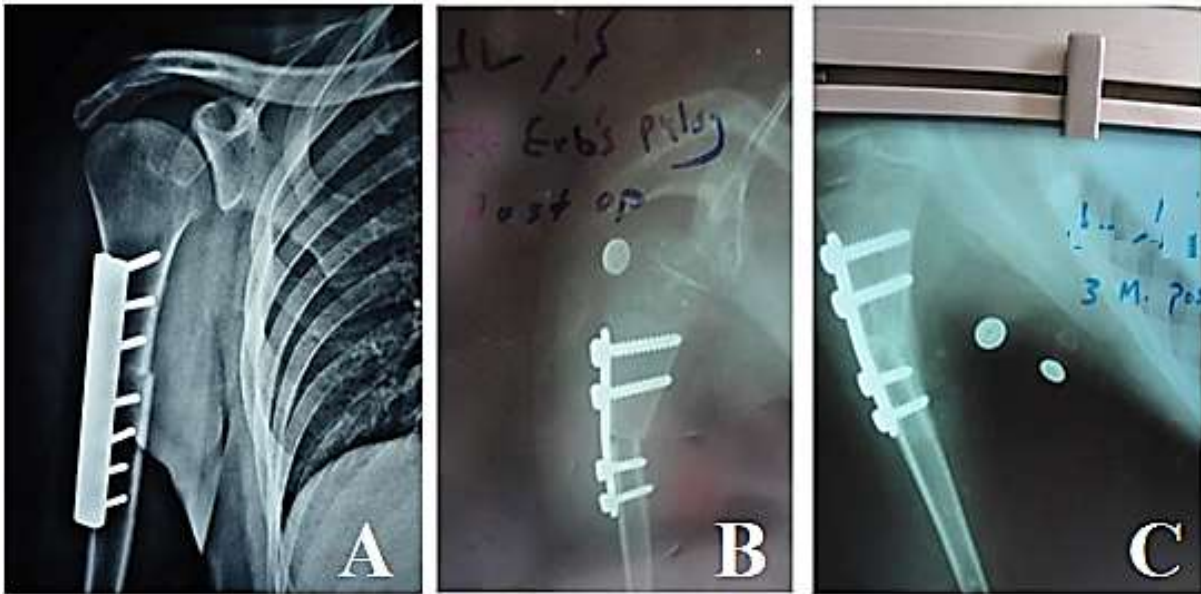


*Figure 8. Hand to mouth function (elimination of trumpet A. Pre-op. ; B. Post-op.)*



*Figure 9. Improved cosmetic appearance after improved external rotation of shoulder and decreased elbow flexion contracture postoperatively ( A. Pre-op. ; B.Post-op. )*





**Figure 10. Post-op. X-rays for two patients in our study ; A- Immediately post-op. ; B and C - Immediately post-op. and 3 months post-op. respectively for other patient.**

#### **4. DISCUSSION**

An internal rotation contracture often results after a residual upper or extended upper trunk lesion secondary to the pull of the normally functioning adductors and internal rotators overpowering the weakened external rotators. A persistent internal rotation contracture will lead to glenohumeral deformity over time (24) . Surgical options depend on the state of glenohumeral joint, If the humeral head is congruent with no shoulder joint deformity, release of the subscapularis and tendon transfer is the procedure of choice. However, if the humeral head is not round or there is joint subluxation, external rotation osteotomy of the humerus is indicated (25). In our study. Selection of patients for derotational humeral osteotomy was done depending on clinical findings and radiological findings. Clinically, all patients had fixed internal rotation contracture deformity of the shoulder joint, with the fact that the average age was 9.5 (range 6.5 to 25) years, therefore the glenohumeral joint dysplasia was highly suspected or certainly present. Radiologically, we use plain X-rays to assess the glenohumeral changes as reported by Al-Qattan (28) who used plain radiographs for assessment of glenohumeral joint dysplasia in their studies. We did the derotational

humeral osteotomy above the deltoid insertion as described in previous studies (3,26,27). This site of osteotomy has advantages of earlier consolidation of the osteotomy site because the proximal part of the humerus consists of cancellous bone (metaphyseal region) . Secondly, the placement of the insertion of the deltoid in a more lateral position provides a mechanical advantage to the tendon (27). In our study, with a follow up period (3-15 months, mean 12 months), we can judge the results which include excellent gain in external rotation of the shoulder (the mean shoulder external rotation was 45° (range, 30° to 60°) and this result is comparable to the results of Bae and Waters (3) and Al- Qattan (28). The excellent gain in external rotation of the shoulder occurs because the osteotomy puts the arm in a functional position although it does not actually create active external rotation. The improvement of forearm supination secondary to external rotation osteotomy of humerus, in our study, is expected and these results are comparable to that reported in previous studies (3,8,29).

Our results showed slight improvements in elbow extension deficit and these results are comparable to the result of Al- Qattan (28) (in Al- Qattan study 15° to 25° deficit of elbow extension pre-operatively which improved to 10° to 15° post-operatively) .In other studies, this improvement was not considered or not quantified.

Price and Grossman (30) emphasized that elbow flexion contracture in Erb's palsy is difficult to explain pathophysiologically. The contracture often is as much a functional as an aesthetic disability, especially in view of the limb length discrepancy seen in these children. Elbow flexion contracture may be explained by a stronger biceps than triceps. Another explanation for the elbow flexion contracture is muscle imbalance and cross-innervation, which is frequently found after spontaneous recovery of Erb's palsy (31). Another explanation that several children with shoulder internal rotation contracture stand with the shoulder slightly abducted (and hence the elbow falls into slight flexion) to place the limb away from the body in a better functional position. This flexed posture of the elbow may contribute to contracture, possibly explaining the slight improvement of elbow flexion deformity after humeral osteotomy (21,28) .

Our results showed that the osteotomy did not improve shoulder abduction which is unlike the observation of other investigators (19,21,22,25,28)

Although there is slight improvement in active range of internal rotation in our results



, which was comparable to the results of John et al (27) (10° to 20° increase of active internal rotation in John et al study), this had no significant change in function as all patients in our study had grade two or three in hand to spine function preoperatively and postoperatively according to Mallet grading system. During the follow up period, there was no nonunion or malunion of the osteotomy or worsening of the obtained improvement in range of shoulder external rotation and elbow flexion contracture and this was comparable to the results of John et al (27) Al-Qattan (25,28), Al-Zahrani (32) and Bae and Waters (32). We found that 16.7% (5 patients in this study) had a hypertrophic scar. In the study of Al-Qattan (28), he had 5 children developed unsightly hypertrophic scars from total 15 patients in his study. Although it is mentioned theoretically, we have not found a figure about this complication in the reviewed available articles.

## **5. CONCLUSIONS**

The derotational humeral osteotomy is an attractive treatment option for improving shoulder external rotation in patients with Erb's palsy with internal rotation contracture, and/or glenohumeral joint deformity. The procedure is safe and has a high rate of satisfaction functionally and aesthetically, with this mode of treatment, intensive physical therapy is not needed; this makes it easier to manage younger patients where a high level of cooperation and compliance is needed. Authors recommended that the status of the glenohumeral joint rather than the age of the patient should guide surgical planning, Intra-operative assessment of external rotation (achieved by osteotomy) is vital to avoid overcorrection because a fixed external rotation posture is functionally more disabling than the internal rotation contracture. And the aim of the derotational osteotomy with its expected functional and aesthetic results should be well explained to the patients and/or their parents. However, further studies still needed for further evaluation

**Ethical Clearance** Ethical clearance and approval of the study are ascertained by the authors. All ethical issues and data collection were in accordance with the World Medical Association Declaration of Helsinki 2013 for ethical issues of researches involving humans, verbal and signed informed consent obtained from all parents / patients. Data and privacy of patients were kept confidentially. .

**Conflict of interest:** Authors declared none

**Funding:** None, self-funded by the authors

## References

1. Stutz C. Management of Brachial Plexus Birth Injuries: Erbs and Extended Erbs Palsy. In: *Operative Brachial Plexus Surgery*. Springer; 2021. p. 583–90.
2. Jeevannavar JS, Appannavar S, Kulkarni S. Obstetric Brachial Plexus Palsy-A Retrospective Data Analysis. *Indian J Physiother Occup Ther*. 2020;14(1).
3. Waters PM, Bae DS. The effect of derotational humeral osteotomy on global shoulder function in brachial plexus birth palsy. *JBJS*. 2006;88(5):1035–42.
4. Ruchelsman DE, Pettrone S, Price AE, Grossman JAI. Brachial plexus birth palsy. *Bull NYU Hosp Jt Dis*. 2009;67:83–9.
5. Heise CO, Martins R, Siqueira M. Neonatal brachial plexus palsy: a permanent challenge. *Arq Neuropsiquiatr*. 2015;73:803–8.
6. Gbozee L, Abubakar MK, Hennings SS. Obstetric brachial palsy: Challenges of management in a developing country. *Arch Int Surg*. 2019;9(3):57.
7. Abdou M, Abdelgawad A. Birth Injuries and Orthopedic Manifestations in Newborns. In: *Pediatric Orthopedics and Sports Medicine*. Springer; 2021. p. 61–8.
8. Thatte MR, Mehta R. Obstetric brachial plexus injury. *Indian J Plast Surg Off Publ Assoc Plast Surg India*. 2011;44(3):380.
9. Joyner B, Soto MA, Adam HM. Brachial plexus injury. *Pediatr Rev*. 2006;27(6):238–9.
10. Alfonso I. Pathogenesis of obstetric brachial plexus palsy. *Pediatr Neurol*. 2008;39(5):371.
11. Canale T, James H. Nervous system disorders in children in: *Campbells Operative Orthopaedics* Editors: Campbell W, Canale S. , 11th ed. St. Louis: Mosby- Elsevier; 2013, PP1481.
12. Al-Mohrej OA, Mahabbat NA, Khesheaim AF, Hamdi NB. Characteristics and outcomes of obstetric brachial plexus palsy in a single Saudi center: an experience of ten years. *Int Orthop*.

- 2018;42(9):2181–8.
13. Thatte MR, Hiremath A, Nayak N, Patel N. *Obstetric Brachial Plexus Palsy. Diagnosis and Management Strategy. J Peripher Nerve Surg (Volume 1, No 1, July 2017). 2017;2:9.*
  14. Vaquero G, Ramos A, Martinez JC, Valero P, Nunez-Enamorado N, Simon-De las Heras R, et al. *Obstetric brachial plexus palsy: incidence, monitoring of progress and prognostic factors. Rev Neurol. 2017;65(1):19–25.*
  15. Gunes A, Gumeler E, Akgoz A, Uzumcugil A, Ergen FB. *Value of shoulder US compared to MRI in infants with obstetric brachial plexus paralysis. Diagnostic Interv Radiol. 2021;27(3):450.*
  16. Gad DM, Hussein MT, Omar NNM, Kotb MM, Abdel-Tawab M, Yousef HAZ. *Role of MRI in the diagnosis of adult traumatic and obstetric brachial plexus injury compared to intraoperative findings. Egypt J Radiol Nucl Med. 2020;51(1):1–7.*
  17. Agranovich OE, Oreshkov AB, Mikiashvili EF. *Treatment approach to shoulder internal rotation deformity in children with obstetric brachial plexus palsy. Pediatr Traumatol Orthop Reconstr Surg. 2018;6(2):22–8.*
  18. Abdelgawad AA, Pirela-Cruz MA. *Humeral rotational osteotomy for shoulder deformity in obstetric brachial plexus palsy: which direction should I rotate? Open Orthop J. 2014;8:130.*
  19. Aly A, Bahm J, Schuind F. *Percutaneous humeral derotational osteotomy in obstetrical brachial plexus palsy: a new technique. J Hand Surg (European Vol. 2014;39(5):549–52.*
  20. Acan AE, Gursan O, Demirkiran ND, Havitcioglu H. *Late treatment of obstetrical brachial plexus palsy by humeral rotational osteotomy and lengthening with an intramedullary elongation nail. Acta Orthop Traumatol Turc. 2018;52(1):75–80.*
  21. Assunção JH, Ferreira AA, Benegas E, Bolliger R, Prada FS, Malavolta EA, et al. *Humeral internal rotation osteotomy for the treatment of Erb-Duchenne-type obstetric palsy: clinical and radiographic results. Clinics. 2013;68:928–33.*
  22. Bae DS, Waters PM. *External rotation humeral osteotomy for brachial plexus birth palsy. Tech Hand Up Extrem Surg. 2007;11(1):8–14.*
  23. Al-Qattan MM, El-Sayed AAF. *Obstetric brachial plexus palsy: the Mallet grading system for shoulder function—revisited. Biomed Res Int. 2014;2014.*
  24. Abzug JM, Kozin SH. *Current concepts: neonatal brachial plexus palsy. Orthopedics. 2010;33(6):430–5.*
  25. Al-Qattan MM, Al-Husainan H, Al-Otaibi A, El-Sharkawy MS. *Long-term results of low rotation humeral osteotomy in children with Erb's obstetric brachial plexus palsy. J Hand Surg (European Vol. 2009;34(4):486–92.*
  26. Cuesta FJG, Parts FL, Lopez FJG SJ. *The role of bone operations as palliative surgical treatment*

- for the sequelae of obstetrical brachial paralysis in the shoulder. Acta Orthop Belg. 1982;48:757–61.*
27. Kirkos JM, Kyrkos MJ, Kapetanios GA, Haritidis JH. *Brachial plexus palsy secondary to birth injuries: Long-term results of anterior release and tendon transfers around the shoulder. J Bone Joint Surg Br. 2005;87(2):231–5.*
28. Al-Qattan MM. *Rotation osteotomy of the humerus for Erb's palsy in children with humeral head deformity. J Hand Surg Am. 2002;27(3):479–83.*
29. Shamma A, Mansour G, Mohamed MS. *Functional Outcome of Humeral External Rotation Osteotomy in ERB's Palsy. Egypt J Hosp Med. 2019;74(5):1064–8.*
30. Price AE, Grossman JA. *A management approach for secondary shoulder and forearm deformities following obstetrical brachial plexus injury. Hand Clinics. 1995 Nov 1;11(4):607-17.*
31. Chuang DC, Ma HS, Wei FC. *A new evaluation system to predict the sequelae of late obstetric brachial plexus palsy. Plastic and reconstructive surgery. 1998 Mar 1;101(3):673-85.*
32. Al-Zahrani S. *Combined Sever's release of the shoulder and osteotomy of the humerus for Erb's palsy. Journal of Hand Surgery. 1997 Oct;22(5):591-3.*